

Pilonidal disease: Origin from follicles of hairs and results of follicle removal as treatment.

1980-2006: An Update

I published the following article 26 years ago. The methods I described to treat pilonidals have remained useful. My concepts of pilonidal origin have been confirmed and strengthened by observations of 600+ cases, many referred as complex failures of other methods of treatment. My experience has nudged my opinions on some minor points. I take this opportunity to insert those changes into the text below ***changes in BOLD TEXT**.

John Bascom, M.D., Ph.D., Eugene, OR.

Contrary to current concepts, shafts of hairs apparently are not the source of most pilonidal disease. Instead, follicles of hairs seem to be the source. Pilonidal disease progresses through five stages. Accumulation of hair, within a chronic pilonidal abscess is a late and secondary phenomenon. The acute abscess is drained only. Over the chronic abscess the distended hair follicles are removed individually from the gluteal cleft. In addition, the cavity of the chronic abscess is cleaned out through incisions placed parallel to, but to one side of, the cleft. Acute abscesses are similarly treated 5 days after drainage. Cavity walls are not excised. They are allowed to fall closed and heal. An epithelial tube, when found, is dissected out through incisions beside the cleft. Nonhealing wounds are effectively treated with Monsel's Salt. Fifty patients were treated in the author's office under local anesthesia. Disability averaged 1 day. Healing time, without disability, averaged 3 weeks. Recurrences in four patients were healed in an average of 2 weeks.

The issue of the origin of pilonidal disease remains open. Confusion over origin increases the existing uncertainty about treatment (1,2,4-9,11,16,17). With stages of development of the disease poorly understood, treatment is randomly applied. Disability, recurrences, nonhealing and overtreatment too often plague the patient and surgeon alike.

Hair has long been considered to be the cause of pilonidal disease (3,9,10). It now appears to be a secondary invader (11). A more likely cause lies in normal follicles which lie in the midline of the gluteal cleft. Forces, only partially understood, enlarge these follicles. Infection of the enlarged follicles leads, by stages, to the cysts and sinuses of the usual surgical descriptions.

(I now believe both hair and/or follicles start pilonidal disease—the first more important in one case, the second in another. I see raw areas strictly confined to the midline. The midline is the only area where hairs smash into skin cells head-on. Factors that further convince me of the

importance of hair are the presence of scales or barbs on hairs, the effect of vertical cleft walls in lining up hairs toward the midline, the shift of cleft walls imparted by a walk appears to combine with barbs on hairs in imparting motion to hairs, thus forcing hairs against midline cells where hairs puncture skin or accumulate in stretched follicles.)

This article presents evidence for the follicular origin of most pilonidal disease. Treatments fitted to each stage of the disease will be described and results in 50 patients summarized.

METHODS

Fifty consecutive patients with pilonidal disease were treated, all in the office under local anesthesia. Acute abscesses received immediate drainage only.

Drainage incisions lay parallel to the cleft and a finger's breadth to one side. Neither drains nor antibiotics were used for acute abscesses.

Chronic abscesses were treated by excision of

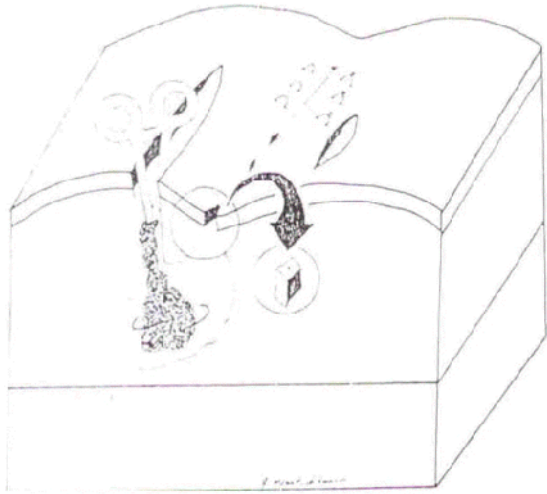

Fig. 1. Treatment of the chronic abscess by individual follicle removal and scrub-out through a lateral incision.

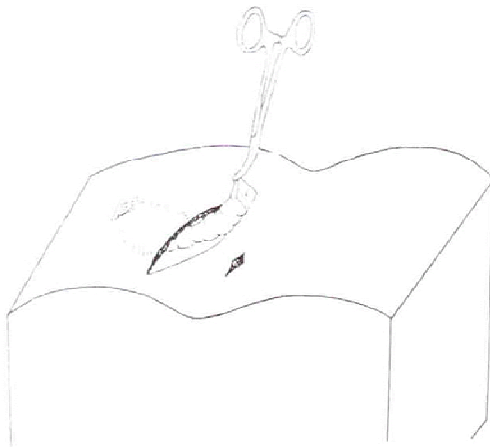

Fig. 2. Dissection through a lateral incision to remove an epithelial tube. Midline incisions, which may fail to heal if long, are kept as short as possible. **(I rarely needed to excise tube for tunnels rarely accumulate epidermis. I leave in place most tunnels, simply drag gauze through them to clean out hair and granulations.**

enlarged follicles from the midline skin. Acute abscesses which had been drained 5 days before **(we now wait 10 days)** were treated by similar **(follicle)** excision. One to 10 follicles were removed, individually, if possible. **(Cleft lift operations succeed so well we now turn to them earlier in cases of multiple pores, deep clefts and slowly healing wounds. Follicle removal is still our**

treatment of choice for single or few pits in suitable patients as described in this 1980 article, a choice urged on by its simplicity, minimal disability and adaptability to office treatment.) The specimens removed weighed under 1 gm/patient. Midline incisions longer than 7 mm were avoided whenever possible but when present, were loosely sutured.

An incision parallel to and to one side of the cleft opened the chronic abscess cavity widely through its side. The incision undermined the midline skin. Gauze pushed through this incision scrubbed the cavity free of hair and granulations as shown in Fig. 1. Side incisions were left unsutured. **(We now excise from the incision border a small <1 cm plug of skin to delay skin closure. This is a substitute for wound packing which is uncomfortable, time consuming and unnecessary.)** Cavity walls were rarely excised. Again, neither packs nor antibiotics were used. Epithelial tubes, when found, were dissected through big lateral incisions, leaving small midline defects of 7 mm, as shown in Fig. 2.

Nonhealing midline wounds were saucerized. They usually had resulted from prior midline surgery done elsewhere. Every 4 days they were repacked with cotton soaked in Monsel's Salt which was left in place between visits. Monsel's Salt (Mallinckrodt, Inc., St. Louis, MO.) is a ferric subsulfate, a syrupy brown astringent sometimes used to control surface bleeding from the cervix or nasopharynx. For all patients daily showers were encouraged.

(Though we believed Monsel's Salt was the best treatment available for unhealed wounds in 1980, we have since found that Monsel's rarely healed chronic wounds and we have abandoned its use, especially since it, in one patient, burned holes in his shorts! Instead, to heal nonhealing wounds quickly and securely, we use the cleft lift operation. For a description of the cleft lift operation see: http://www.pilonidal.org/medical_profes.htm {Cleft Lift Published Article--2002})

Dressings or pads protected clothing as needed. Wounds were examined weekly and picked free of hair. Antibiotics were used in four patients with late cellulitis.

RESULTS

Fifty patients were treated, of whom 29 were men. Twenty-four presented with acute abscesses. Five epithelial tubes were found, all in men with long - standing disease. Follow-up - on all but one patient, or 98% -- averaged 24 months.

The mean disability was 1 day. Thus half of the patients were back at school or work the day after the operation. The mean wound healing time, free of disability, was 3 weeks. Recurrences appeared in four

patients, or 8%. All recurrences healed by three weeks after (office) treatment. There were no second recurrences.

DISCUSSION

Despite abundant literature on the subject, pilonidal disease still seems to be poorly treated. Forty percent of patients entering this series had not been cured by prior treatment elsewhere. Abscesses had been drained 1 to 7 times before. Under-treatment, the failure to remove a diseased follicle, was the most common fault.

Overtreatment, cutting large midline wounds, can also invite hospitalization and disability as the armed services have learned (7). Even in this small series there were four patients referred who were unhealed, one after a month of hospitalization, and others after months of disability which followed unsuccessful midline surgery.

The planning of good treatment needs an understanding of the source and stages of pilonidal disease. Midline pits, often smaller than a printed period on this page, are a common finding in pilonidal disease. **(For pictures of pits and treatment, see**

www.pilonidal.org/knowledge_base/pictures.htm.)

When pilonidal cavities are explored through lateral incisions, the pilonidal abscess cavity leads the exploring instrument to the underside of such a pit which has blown out (**, or better, the instrument leads to a pit that has “blown in” to fat its contents. The contents start the pilonidal abscess.**). From adjacent pits a pasty white material can be expressed. These findings implicate midline pits and their contents as a possible source of the disease. **(Findings do not just implicate pits, they prove beyond question that pits start primary pilonidal disease.)**

(To see color pictures of the following magnified tissue slides, look under on this web site under Medical Professionals where find, “Bascoms Cleft Lift Presentation”, and use the web or PowerPoint version.) Thirty such pits were examined microscopically. Study revealed evidence that pits are distorted hair follicles. First, beside some pits were found moderately distended follicles which, in turn, lay beside normal hair follicles, as shown in Figs. 3 & 4. A complete spectrum of follicle sizes could be identified, ranging from the normal follicle to the

largest pit. This spectrum of sizes seems clearest evidence that the pits which opened into abscess cavities were originally distended hair follicles. Second, large pits seemed to be distorted follicles because they often held in their center a single hair supported by concentric sleeves of keratin. Third, one section showed the germinal bud of a single hair in the wall of a pit **(I am not as sure as I once was about the terminal bud, but the other evidence grows ever more convincing.)**. And, fourth, most pit positions fit the distribution pattern set by nearby hairs. These midline pits, now identified as enlarged follicles, seemed to be the source of pilonidal disease in 90% of the patients in this series.

Two forces apparently enlarge the normal follicle. Accumulated keratin seems to push on the follicle wall to move it outward. A vacuum pulls on the wall (this will be discussed below.) There may be other forces.

Further study of microscopic sections revealed evidence of multiple stages of pilonidal disease. These stages are sketched in Fig. 5. An infection first forms in and about the enlarged follicle **(forms about the base of the follicle where keratin breaks through and hairs punch through)**. Infection **(incited in fat by the bacteria-laden keratin and hairs)** creates edema, which swells the mouth of the follicle shut. This blocks the escape of follicular contents. It also hides the mouth of the follicle from view.

(To split a hair, pun intended, I find hair itself is not the trigger that must be removed. I find the body will heal overlying skin despite hair shafts consciously left behind, in place in abscess walls. The essential trigger that must be controlled is the hole in the epidermis, often microscopic, where a hair breaks through, formed where a hair lies both inside and outside the body.)

Follicular contents are pushed toward fat by the pressure of pus accumulating in the closed follicle. **(Now I think contents are less pushed by the pressure of pus which forms in fat, not in follicle, but more by the pressure of accumulating keratin and driven-in hairs)** They are also pulled toward the fat by vacuum. The bottom of the follicle blows out, releasing infected contents into fat. An acute pilonidal abscess in fat results. The acute abscess is drained. As edema subsides, the mouth of the follicle reopens. The follicular remnant, now open at both ends, forms the outer twentieth of the chronic abscess cavity, a cavity which blows and sucks, see Fig. 6.

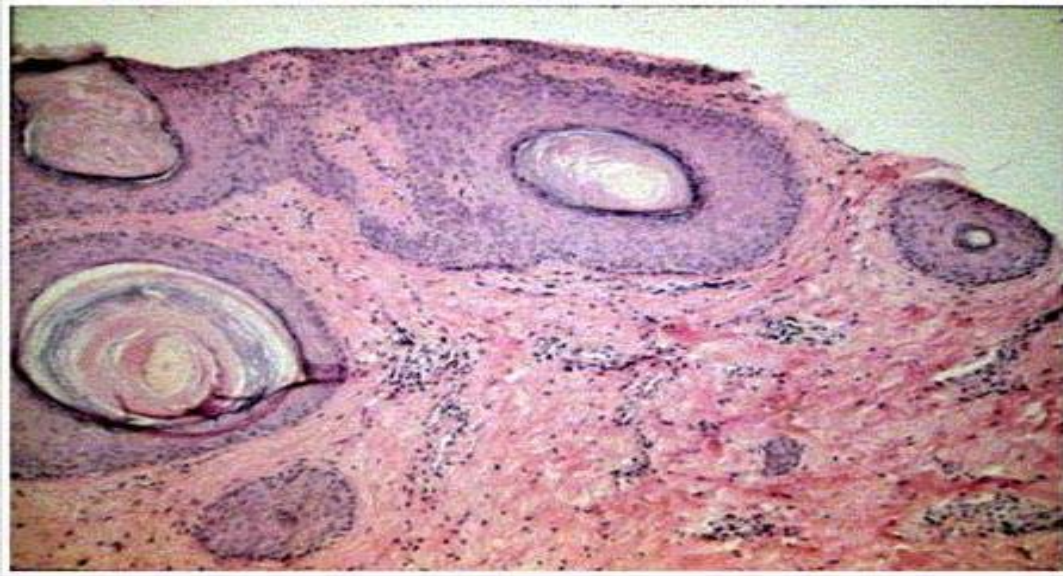


Fig. 3. A progression of follicle sizes from a normal hair follicle on the right to the dilated hair follicle or pit on the left. This is the most conclusive evidence that most midline pits are distorted hair follicles. Note the single hair in the center of the dilated follicle.

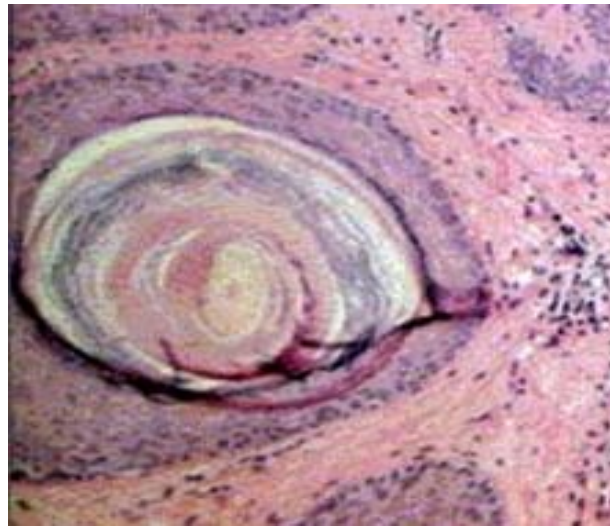


Fig. 4. The dilated follicle showing the accumulation of keratin between the hair shaft and the follicle wall.

As the patient stands, gravity pulls the gluteal tissue away from the sacrum. A vacuum is created and air is sucked into the cavity, passing through the follicular remnant (**to join accumulated pus**). Brearly (3) has measured this vacuum. Vagrant hairs gather in the gluteal cleft. Page (14) had demonstrated the vacuuming in of such hair into a pilonidal cavity. He also demonstrated the one-way motion given a hair by the scales on its surface. Fig. 6 diagrams this process. When the patient sits, gluteal tissues are pushed against the sacrum (**Furthermore, the squeeze of the buttocks seals the exit. We measured the squeeze. To our amazement, to overcome the seal of squeeze,**

pressure in the cavity must exceed 125 mm Hg before fluid drains out of the cavity and onto the chair. Such pressure is enough to push water to above the seated patient's head from the tip of the sacrum! I strongly suspect this pressure of trapped pus drives pus through fat, creates tunnels and creates abscesses distant to the follicle of origin.)

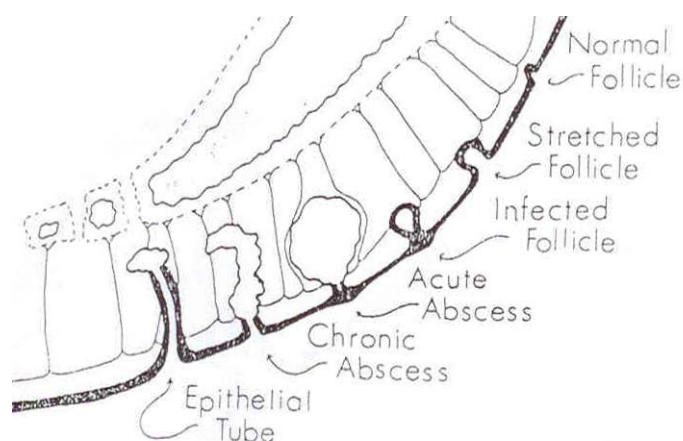


Fig. 5. The stages of pilonidal disease (from top to bottom; (1) normal follicle. (2) Follicle distended with keratin. Fibrous strands suspend follicle and skin from sacrum. (3) Infection of the distended follicle. Edema closes the mouth of the follicle. (4) Rupture of the infected follicle into fat creating an acute pilonidal abscess. (5) Chronic pilonidal abscess. The ruptured follicle which is open at both ends forms the mouth of the this abscess. (6) Epithelial tube. Epithelium from the ragged end of a ruptured follicle has grown down the wall.

An epithelial tube is formed by epithelium advancing down the walls of a chronic abscess cavity (7). **(An epithelial tube should be looked for but is rarely found. It presents itself as tube with smooth lining, it looks like macaroni inserted as an inner wall of the tube, not a tunnel showing the usual rough wall of granulation tissue.)** The source of the advancing epithelium is the ragged end of the blown-out follicle. Such epithelial tubes may extend several centimeters into fat. These observations on the stages of pilonidal disease form the basis of treatment. Incision for drainage relieves the pain of the acute abscess. However, edema prevents anesthesia adequate for extensive surgery, and edema hides the follicles that must be located and removed. For this reason follicle removal is delayed by 5 days **(now we use 10 days)** and drainage alone is used for acute abscesses.

The chronic abscess has walls that fall together and will heal. First the inciting cause, the follicle, must be removed. A small hemostat, exploring the cavity through the lateral incisions, pushes through the offending follicle to identify it. The instrument also firmly rubs the midline skin from underneath. Short streams of pasty material issuing from nearby dilated follicles identify possible sources of recurrence. All visibly enlarged follicles are removed individually. The decision favoring individual removal of the follicles was based on wound healing observations. Wounds about the anus and buttocks heal rapidly. Yet 2 years after pilonidal surgery, some long wounds placed in the midline of the gluteal cleft remain open. Therefore, long midline wounds seem best avoided. Lateral buttock wounds used here gave good access and they

all healed well. **(I no longer fear non-healing in midline wounds because I have learned cleft lift will rescue any wound. Though I have not tried long midline incisions as primary treatment, they have been used with good results by Rickles and others. Midline incisions have the advantage that they destroy enlarged follicles, drain the abscess, are easy to teach, suited to office use and if they are slow to heal they are dependably rescued by cleft lift.)**

Epithelial tubes were identified by examining the deep end of the excised follicle and the interior of the wound. Smooth white epithelium forms a neat tube wall when present. The wall of a chronic abscess is vague, wet and brownish-red. The final stage of pilonidal disease is the large, wet midline wound, usually iatrogenic in origin. For such wet and nonhealing wounds, full strength Monsel's Salt is more effective than silver nitrate or surgery, and is more comfortable for the patient. Used after dividing skin bridges and overhangs, it flattens granulation and **(occasionally)** heals such wounds in about 3 months. **(For me, surgery is no longer ineffective. The cleft lift operation heals patients promptly despite years of non-healing and multiple failed operations.)**

Office treatment of pilonidal disease is feasible (1,4,13,16). In this and other series, all patients have been successfully treated as out patients. Yet at present, in the United States 40,000 patients with pilonidal disease are treated each year in civilian hospitals and they average 5.2 days of in-hospital care. The avoidance of hospitalization and the methods that make it necessary could save \$40,000,000/year as well as

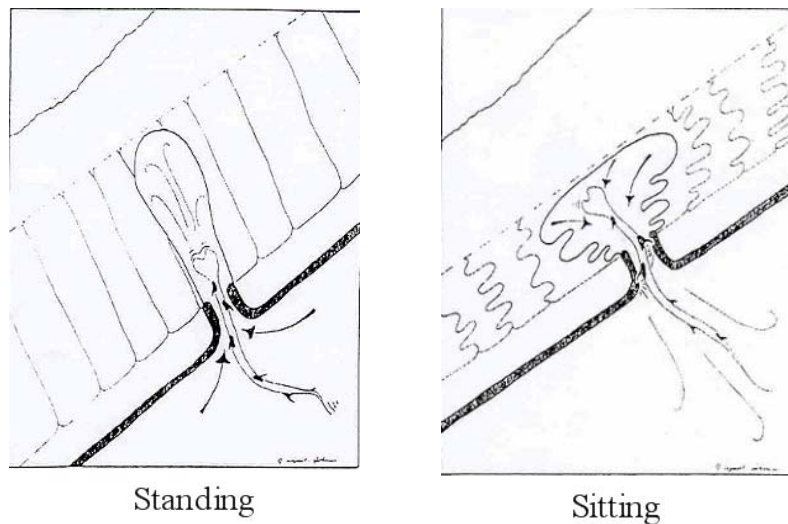


Fig. 6. Ingestion of hair by a chronic pilonidal abscess cavity. Scales on hair convert the in and out flow of cavity contents to a steady inward motion of the hair. *Left, standing; right, sitting.*

much pain and disability created by extensive midline surgery. As to disability, the avoidance of packs and sutures and the wound relaxing effect of incisions placed to one side seem responsible for the unique degree of comfort experienced by patients in this series. The wound healing time of 3 weeks compares favorably with the other methods (1,5,12) and is of minor import, as the patient is rarely aware of the healing wound after the first week. Recurrences also became a minor import once basic pathology is understood, for they respond uniformly and quickly to simple measures. Lord and Millar (12), Abramson (1), and Rickles (16) have described other simple treatments.

Those using the Rickles method are cautioned by the author to avoid its use in the edematous skin of the acute abscess (**because edema hides the pits that must be seen and incised**); to place incisions precisely in the midline thus dividing all enlarged follicles, and to use phenol. (**I discontinued phenol use as inconvenient to use but I still recognize its theoretical advantages as a disinfectant and a destroyer of epidermal remnants. As to the future, the use of fibrin glue may speed recovery.**) Phenol may stimulate wound healing as does Monsel's Salt, a substance (**no longer used**) that can be used after operation without anesthesia

References

1. Abramson B: Excision and delayed closure of pilonidal sinuses. *Surg Gynecol Obstet* 144:205, 1977
2. Bose B, Candy J: Radical cure of pilonidal sinus by Z plasty. *Am J Surg* 120:73, 1970
3. Brearley R: Pilonidal sinus; a new theory of origin. *Br. J Surg* 43:62., 1955
4. Grile G: Thirteen shortcuts in office surgery. *Surg Clin North Am* 55:1025, 1975
5. Farringer J, Pickins D: Pilonidal cyst, an operative approach. *Am J Surg* 135:262 1978
6. Gage A, Dutta P; Cryosurgery for pilonidal disease *Am J Surg* 133:249, 1977
7. Hardaway R: Pilonidal cyst – neither pilonidal nor cyst *Arch Surg* 76:143, 1958
8. Hoexter R: Water-Pik in pilonidal care *Dis Colon Rectum* 19:470, 1976
9. Karydakis G: New approach to problem of pilonidal sinus *Lancet* 2:1414, 1973
10. Kovalcik P: Relevancy of the Barbers interdigital pilonidal sinus *JAMA* 224:1650, 1973
11. Lamke L, Larsson J, Nevlen B: Results of different types of operation for pilonidal sinus *Acta Chir Scand* 140:321, 1974
12. Lord P, Millar D: Pilonidal sinus: a simple treatment, *Br J Surg* 52:298, 1965
13. Lord P: Anorectal problems; etiology of pilonidal sinus *Dis Colon Rectum* 18:661, 1975
14. Page B: The entry of hair into a pilonidal sinus *Br. J Surg*, 56:21, 1969
15. Patey DH: A reappraisal of the acquired theory of sacrococcygeal pilonidal sinus and an assessment of its influence on surgical practice *Br J Surg* 56:463, 1969
16. Rickles J: Ambulatory surgical management of pilonidal sinus *Am Surg* 40:237, 1974
17. Thomas D: Pilonidal sinus: a review of the literature and a report of 100 cases *Med J Aust* 2:184, 1968

