

Pilonidal Sinus Disease

The Conservative Approach

MAJ John H. Armstrong, MD, MC, USA, COL Peter J. Barcia, MD, MC, USA

Objective: To examine the role of conservative, nonexcisional methods in the treatment of pilonidal sinus disease.

Design: Pilot nonrandomized cohort study and follow-up retrospective study.

Setting and Patients: In the pilot study, all patients treated for pilonidal sinus disease consecutively over 3 years at an Army community hospital, and in the follow-up study within a closed federal population, all patients admitted with a diagnosis of pilonidal sinus disease over 17 years to an Army medical center.

Interventions: Conservative, nonexcisional therapy (meticulous hair control by natal cleft shaving, improved perineal hygiene, and limited lateral incision and drainage for abscess) with initial comparison to excisional procedures.

Main Outcome Measures: Occupied-bed days for con-

servative vs excisional therapy during a 3-year pilot study and the number of admissions and procedures performed for pilonidal sinus disease at an institution dedicated to conservative treatment alone.

Results: Complete healing over 83 occupied-bed days was demonstrated in 101 consecutive cases managed during 1 year with the conservative method, whereas slower healing over 4760 occupied-bed days was observed in 229 patients undergoing 240 operative procedures during the preceding 2 years. With application of conservative treatment over 17 years, only 23 excisional operations were performed.

Conclusions: Conservative therapy effectively controls pilonidal sinus disease in the nonoperative outpatient setting while promoting near-normal work status and is preferred over excisional operations.

(Arch Surg. 1994;129:914-918)

PILONIDAL SINUS disease is an acquired condition, usually seen in young adults, manifest by midline pits in the natal cleft and associated with hair. The underlying pathophysiologic feature is enlarged hair follicles due to midline vacuum and pulling forces; when plugged with hair or keratin, the follicles rupture, leading to a foreign-body reaction within the presacral subcutaneous tissue and subsequent acute and chronic abscess.¹ The seemingly simple nature of this entity has been overshadowed by the history of its treatment, focused on the surgical extirpation of "diseased tissue." The attendant morbidity of these treatments, in terms of chronic wounds, patient productivity lost to convalescence, and recurrence, has been impressive.² The recent trend has been toward more conservative therapy, minimizing

tissue loss. An extension of this thinking emphasizes perineal hygiene, including hair control, for management of the condition in general, with lateral incision and drainage reserved for acute abscess. Our study reports a pilot comparison between conservative nonoperative therapy and standard excisional procedures in the management of pilonidal sinus disease and then provides follow-up of long-term experience in the application of a generally exclusive conservative policy to a large patient population.

From the Department of Surgery,
General Surgery Service, Tripler
Army Medical Center, Hawaii.

*See Invited Commentary at
end of article.*

METHODS

PILOT-COMPARISON STUDY

The pilot-comparison study was performed at an Army training center hospital (Montcrief Army Community Hospital, Ft Jackson, SC) covering a 3-year period (1973 to 1975). Army recruits undergoing basic training constituted the dominant patient population, and regulations required hospitalization for all soldiers not fit for full duty. The disposition requirement resulted in a semiclosed patient population and provided a unique opportunity to monitor convalescence. The charts of all patients treated with excisional surgery for pilonidal sinus disease (N=229) were retrospectively reviewed for the 2 years prior to instituting conservative therapy alone. A variety of procedures were performed by six surgeons and included excision with marsupialization, open packing, partial or complete primary closure, and plastic closure, such as skin grafting, Z-plasty, and rotation flaps.

Conservative therapy was then administered prospectively by one of us (P J.B.) for 101 consecutive patients over the following year. The protocol required patient education regarding the nature of the condition and the importance of perineal hygiene, simple lateral incision and drainage for acute abscess, meticulous hair control, and avoidance of certain exercises, such as sit-ups and leg-lifts. Hair control involved a weekly 5-cm strip shave within the natal cleft from the anus to the presacrum until healing occurred, with further weekly shaving for recurrence (Figure). Healing was defined as an uninflamed, nondraining natal cleft with shrinkage of the pits.

The specific parameters measured for both groups were occupied-bed days, indicative of patient convalescent time, and the number of operations performed. A general assessment of the number of chronic wounds was made as well. Recurrence rates were not specifically monitored with either therapy.

FOLLOW-UP STUDY

The protocol for exclusive conservative management of pilonidal sinus disease was then applied from 1975 to the

present for the federal population (232,000) served by Tripler Army Medical Center (565 beds) in Hawaii. Approximately half of this population, representing a significant age group at risk of pilonidal sinus disease, are active-duty military personnel with dependents. Because Tripler provides all surgical care for these patients for the duration of assignments to Hawaii (average, 4 years), the population is largely closed. Intense education regarding conservative therapy was provided to all military clinics serving as the surgical referral base during the first decade of the study. The pilot study protocol was modified in Hawaii in one way: exercise (sit-up and leg-lift) restrictions for patients with chronic disease were eliminated, favoring instead the use of a small pillow between the natal cleft and the ground.

To follow up this policy, a retrospective review of all admissions to Tripler Army Medical Center with the primary diagnosis of pilonidal sinus disease was performed for the complete calendar years during which this policy was in effect (1976 to 1992). The database was located through the US Army Health Service Command Patient Administration Systems and Biostatistic Activity by *International Classification of Diseases, Ninth Revision, Clinical Modification*³ coding for pilonidal cyst or sinus, with or without abscess. The database included age, sex, diagnosis, date of admission, date of disposition, and procedures performed. Admissions represented patients requiring treatment in the operating room, including sedation (sedation was not permitted in the outpatient clinic), or initial disposition away from the barracks setting (ie, hospitalization while not fit for active duty). Care was provided by surgical residents under the supervision of attending staff. The number of days hospitalized was not calculated because disposition meant either discharge from the hospital or return to duty, and this could not be better defined from the database. To gain better insight into more recent admissions, a chart review for those patients identified by the database as admitted for pilonidal sinus disease during the last 3 calendar years (1990 to 1992) was completed.

RESULTS

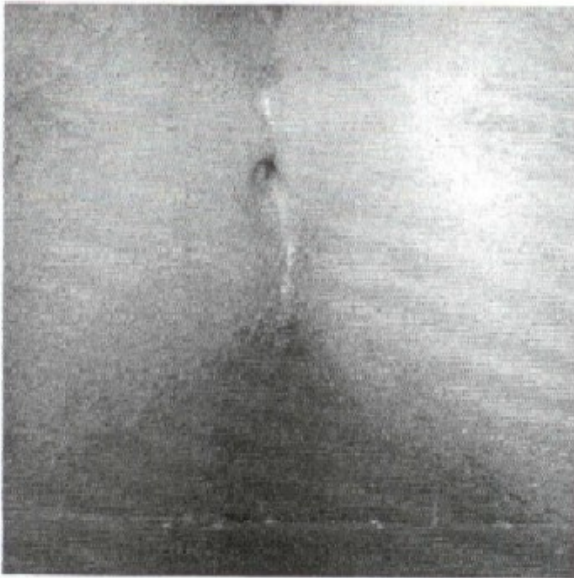
PILOT-COMPARISON STUDY

Over the 2-year interval preceding the conservative protocol, a total of 240 operations were performed in the excisional group of 229 patients. This required a total of 4760 occupied-bed days, or an average of 21 occupied-bed days per patient (Table 1). The prolonged hospitalization is explained by the Army basic trainee population, who, by regulation, could not be discharged from the hospital until they were fit for duty. Chronic wounds (number not determined) did occur in the excisional group. During the subsequent year, the conservative method was applied to 101 consecutive

patients from the same population, requiring no operations, with a total of 83 occupied-bed days. There were no unhealed wounds in the patients treated with conservative therapy.

FOLLOW-UP STUDY

Over 17 years at Tripler Army Medical Center, there were 150 admissions for pilonidal sinus disease from the federal population in Hawaii. It is estimated that through this time, over 350 000 people were at risk between ages 15 and 35 years. Population characteristics and procedures are shown in Table 2. Only 23 excisional procedures were performed over the 17-year period. A dramatic reduction in admissions for pilonidal sinus disease



A 5-cm strip shave within the natal cleft from the anus to the presacrum.

was demonstrated over the study period, decreasing from 68 in the first 4 years to 15 over the last 4-year interval.

The chart review revealed nine patients who were admitted for operative management of pilonidal sinus disease during 1990 through 1992. Five patients required incision and drainage for abscess, with admission required for disposition by regulation. Four excisional procedures were performed. Only one was for chronic pilonidal sinus disease recalcitrant to conservative therapy. This 14-year-old patient had a transverse bridge of tissue across the natal cleft, creating a deep dimple that consistently collected hair and debris; despite weekly shaving by one of us (P.J.B.) for 2 months, drainage persisted. One patient required revision of a pilonidal hypertrophic scar following excision performed elsewhere 1 year prior to presentation. The third patient had a wound fistula as a tract opening through a previous lateral drainage site for pilonidal abscess. The fourth patient, 8 years of age, had an uninfected but enlarging pilonidal cyst. Occupied-bed days were minimal for all nine patients.

COMMENT

The history of treatment for pilonidal sinus disease includes many well-intentioned attempts to surgically extirpate the problem. The morbidity of such efforts has been well documented: 80,000 US Army soldiers with pilonidal sinus disease were hospitalized for an average of 55 days each during World War II,⁴ and 2075 US Navy sailors required 90,392 sick days during 1 year of the Vietnam conflict for the condition.⁵ The resulting chronic, nonhealing wounds have spawned extensive literature regarding further extensive surgeries.⁶

Based on the several components of this study, we believe that pilonidal sinus disease is best controlled with

Treatment Arm	Interval, y	No. of Patients	No. of Operations	No. of Occupied Bed Days
Excisional	2	229	240	4760
Conservative	1	101	0	83

Table 2. Follow-up Study: Admissions During Conservative Therapy Protocol Over 17 Years

	No. of Patients
Total Admissions*	150
Sex, M/F**	122/28
Procedures	
Lateral incision & drainage	110
Excision	23
Not specified	17
Admissions by time interval	
1976-1979	68
1980-1983	37
1984-1987	26
1988-1991	15
1992	4

* Mean age of patients was 23 years (range, 7 to 58 years). ** Male-to-female ratio was 4:1.

conservative, nonoperative methods. There is no unhealed pilonidal surgical wound, and the patient maintains near normal work status. Conservative therapy is very cost effective by transferring treatment from the operating room/inpatient setting to the outpatient clinic. The initial pilot study led to implementation of conservative therapy for the federal population in Hawaii over the past 17 years, and our impression of effective management has been confirmed by finding only 23 instances of excisional operations covering an effective population of 350,000 at risk during this time. Over the past 3 years, only four excisional operations were performed; of these, one represented a wound complication from previous excision elsewhere and another, inadequate incision and drainage for acute abscess. Incision lateral to the natal cleft midline for acute abscess is essential to avoid creating a midline wound in an adverse environment, where traction and vacuum forces trap debris and bacteria and act against wound contraction and healing.⁷ Simple incision and drainage may result in no symptom recurrence in up to 60% of patients who present with acute pilonidal abscess.^{8,9}

Recurrence was not monitored specifically in this study, but no recurrence significant enough to require surgery or hospitalization appeared. Conservative management requires weekly shaving for any sign of recurrence, as well as renewed perineal hygiene. It appears that pilonidal sinus disease is a self-limited condition that disappears with age (usually by 30 years). Control represents a better goal than urgent cure. Thus, recurrence becomes a simple management issue and not a treatment failure. The situation for recurrence

after excisional therapy is much more complex because scarring and tissue distortion seem to trap the natal cleft in unyielding pathophysiologic states and allow anaerobic bacteria to flourish.⁷ Conservative management may not work as well for excisional recurrence.

Although simple, shaving requires the same attention to detail as any operation. Adequate exposure (taping the buttocks apart) and lighting of the natal cleft are essential to ensure complete shaving of all hair within the natal cleft, 5 cm from the anus to the presacrum. Thin, fine hairs might otherwise be missed. Visible hair within the sinus is easily removed, but no attempt is made to probe for hair within the sinus. Performing the initial shave requires 5 minutes, with subsequent shaves taking 2 to 3 minutes. Interested physician extenders within the surgeon's practice can be trained to provide the protocol care. The end points of shaving are disappearance of patient symptoms and resolution of acute inflammation and discharge. Typically, the pits are observed to be progressively drier and smaller at each shave. Patient education is critical for successful treatment; once educated, the patient becomes the primary manager of this condition. With any prodrome or symptoms of recurrence, the patient resumes weekly shaving and improved perineal hygiene. Family members can be easily trained to assist the patient in managing recurrence. The average patient requires from three to four shavings per episode, with a range from two to eight.

Why does shaving seem to work? Certainly it controls a factor in the condition, but only 50% of patients with pilonidal sinus disease are found to have hair within the cyst/sinus. Hair likely has three pathophysiologic roles: retained hair within a ruptured follicle, secondary invader through an existing enlarged follicle, and mechanical irritator of pilonidal wounds.^{7,10} Hair in these latter two roles maintains the adverse environment within the natal cleft¹¹; hair control addresses these dominant roles and helps the patient focus on perineal hygiene. This, in turn, may prevent follicular plugging with keratin.

Conservative management converts pilonidal sinus disease strictly to an outpatient clinic entity, as manifested by the 78% decrease in already low admissions between the first and last 4 years of the follow-up study. Promulgation of the protocol and its results to referring clinics, as well as education of physicians within the surgery clinic, have been essential to refocus expectations. The definitive cure of pilonidal sinus disease requires patience and the passage of time. The decreasing number of excisional procedures over the 17 years attests to surgeon acceptance of the protocol; however, the very small number of excisional procedures performed illustrates that the temptation to "cut it out" is still present.

A question may be raised regarding the closed nature of the military population: Is it possible that patients seek civilian care, or simply endure their condition while in Hawaii and, on moving to another station, receive excisional therapy?

Certainly this is possible, although unlikely. We have received no negative comments from our referral clinics, command, or patients. Most chronic disease is now managed at the level of the primary care clinic, and the acute abscess is usually drained in the surgical clinic.

CONCLUSION

Pilonidal sinus disease is effectively controlled with conservative, nonoperative therapy in the outpatient setting. The chronic disease is managed with a weekly 5-cm strip shave, anus to presacrum, with an emphasis on perineal hygiene, until symptoms resolve. Recurrent disease is managed similarly. The acute abscess requires lateral incision and drainage, followed by strip shave. Unhealed, chronic surgical wounds are prevented, and work modifications are minimal. The role for excisional procedures, therefore, is quite limited.

The assertions and opinions contained herein are the private views of the authors and are not to be construed as official or as reflecting the views of the Department of the Army or the Department of Defense.

Presented at the 65th Annual Meeting of the Pacific Coast Surgical Association, Sacramento, Calif, February 21, 1994.

Reprint requests to Department of Surgery, General Surgery Service, Tripler Army Medical Center, H1968595000 (COL Barcia).

REFERENCES

1. Bascom JU. Pilonidal disease: long-term results of follicle removal. *Dis Colon Rectum*. 1983;26:800-807.
2. Hanley PH. Symposium: the dilemma of pilonidal disease. *Dis Colon Rectum*. 1977;20:278-298.
3. *International Classification of Diseases. Ninth Revision. Clinical Modification.* Chicago, Ill: American Hospital Association; 1989.
4. Abramson OJ. Outpatient management of pilonidal sinuses: excision and primary closure. *Mil Med*. 1978;143:753-757.
5. Stephens FO, Sloan DR. Conservative management of pilonidal sinus. *Surg Gynecol Obstet*. 1969;129:786.
6. Allen-Mersh G. Pilonidal sinus: finding the right track for treatment. *Br J Surg*. 1990;77:123-132.
7. Bascom JU. Pilonidal sinus. In: Fazio VW, ed. *Current Therapy in Colon and Rectal Surgery*. Toronto, Ontario: BC Decker Inc; 1990:32-39.
8. McLaren CA. Partial closure and other techniques in pilonidal surgery: an assessment of 157 cases. *Br J Surg*. 1984;71:561-562.
9. Jensen SL, Harling H. Prognosis after simple incision and drainage for a first episode acute pilonidal abscess. *Br J Surg*. 1988;75:60-61.
10. Page BH. The entry of hair into a pilonidal sinus. *Br J Surg*. 1969;56:32.
11. Karydakos GE. Easy and successful treatment of pilonidal sinus after explanation of its causative process. *Aust N Z J Surg*. 1992;62:385-389.

DISCUSSION

John U. Bascom, MD, Eugene, Ore: President Christensen, the bard is being quoted today. You are aware of course that he was the first discussant on pilonidals. He said "There is a destiny which shapes our ends; rough hew them how we may." This is a landmark paper. Its recommendations in their usefulness and elegant simplicity exceed all surgical textbooks on

this topic. I congratulate the program chairman and the committee for recognizing the worth of a paper that places surgery in a secondary role in the treatment of pilonidal disease.

I have three points to make. First, don't be oversold. You will discredit this fine study if you learn from it that surgery has no role. The authors and I agree that the acute abscess should be drained or aspirated. For most chronic pilonidals, they show us that shaving should start treatment, but, for those slow to respond, apply minimal surgery to speed control. Use lateral drainage and restrict the removal of midline pits to specimens the size of a grain of rice, a technique that in my hands gave good control to some 500 patients, with an average disability of 1 day. The authors and I further agree that shaving will not cure big recurrences. The biggest troublemaker in pilonidal disease is wide excision down to periosteum. For recurrences after such procedures, use an eccentrically placed repair that makes the cleft shallow. It brings the incision up out of the cleft and onto the buttock where it will heal. Healing is secure; disability is minimal. Do indeed sell shaving, but don't be oversold.

My second point is, seal the paint to control the disease. Now, by paint I mean epidermis. This is the outer 10th of skin. It is the transparent paintlike layer that keeps bacteria out. Shaving seals the paint in three ways: it clears out the debris catching hairs that foster the growth of anaerobes in the cleft; it makes minute penetrating hairs visible for removal; and it teaches patients to clean and oxygenate the anaerobes every day. To understand why shaving works, consider the following.

There is no inherent weakness in midline skin. Instead, cleft conditions create disease in any skin lying there. These slides show how fresh, full-thickness skin was pulled across the midline (which was good) against the sacrum in this patient (which was bad because it deepened the cleft). One year later, she returned with these six typical pilonidal pits. Notice that they are exactly in the midline. They lie in skin that was transferred in from one side. The conclusion is inescapable: midline conditions will create pilonidal disease in any tissue that happens to lie there.

Oxygen kills anaerobic bacteria. Anoxic cleft conditions generate anaerobes, which join keratin in drilling a hole in epidermis. This previously published slide shows the smallest and earliest pilonidal in captivity. At the bottom of this enlarged follicle is the pinhole created by anaerobes and keratin. You can see the keratin invading through the pinhole and the little abscess where keratin meets fat. This is the pinhole that anaerobes help to create and through which these anaerobes invade fat. Thomas Hunt of this Society has pointed out that anaerobic conditions stop healing. In the presence of anaerobes, fibrosis and healing in fat come to a halt. The pinhole is sometimes kept open by hairs that lie half in air and half in fat. However, hair was still present in fat at an autopsy on a pilonidal patient who was asymptomatic for 30 years. Hair in fat does not always need removal. So, seal the paint; help the epidermis to heal. The source of pilonidal disease is cleft conditions and the pinhole. All other changes are secondary to fresh infusions of anaerobes into fat. The authors have shown us how to control this.

My third point is, go and do likewise. This paper comes from a surgeon who had the vision of a simpler method, the integrity to convince many doubters, and the toughness and opportunity to teach and even impose his vision on those who were not convinced. As you return to your programs, send your residents to this paper.

I have two questions. First, the literature shows that shaving

gained popularity as surgeons treated open residuals left by the disastrous wide excisions of World War II. Their teachings were forgotten. I understand that the authors learned shaving from a distinguished member of this society. Am I correct in that, and, why do you think that shaving fell from favor? Finally, what do you say to skeptics who wonder if you have a local reputation that Tripler doesn't treat pilonidals and, therefore, patients tolerate the nuisance and don't come in to see you?

Theodore X. O'Connell, MD, Los Angeles, Calif: I wish to ask the authors what their experience is with depilatory agents rather than with shaving. It seems that it would be easier for the patient to self-apply the depilatories rather than shaving and also get a more consistent and long-lasting hair loss rather than having to continually shave.

Dr Barcia: I, too, would like to thank the organizing committee for selecting this paper. It has been one of my life works. There are not many people who are interested in pilonidal sinus disease to the extent that Dr Bascom and I are, and we jokingly say we comprise a very small club. Most of the members of the Association are aware that Dr Bascom is probably the recognized world authority on the conservative management of pilonidal sinus disease; we respect and appreciate him very much for his help, advice, and thoughts.

In regard to his questions, he has it almost right. In 1965 when I was an intern at Tripler Army Medical Center, during my first operation, COL Tom Whelan, a member of the Association, assisted me in an excisional operation for pilonidal sinus disease. Two years later, COL Tom Nelson came as Chief of General Surgery, working under Dr Whelan. Without explaining why, he decreed that we were not doing any more operations on pilonidal sinus disease except for I and D of abscesses. In the Army, you can do this. When I had been an intern, we had a ward with 14 pilonidal patients or those with perirectal abscesses. I have been told by surgeons who worked during World War II that it was very common to have whole wards full of patients recovering from pilonidal surgery. This was probably an inflicted problem because of unnecessary operations.

Dr Bascom asked the question, why do I think that conservative therapy gained favor after World War II and then fell out of favor? It is because of the nature of surgeons. The shaving technique and conservative therapy is "not really an operation," so it is considered beneath the dignity of surgeons. Based on my experience, this method requires extraordinary commitment lest surgeons return to their natural inclinations. The last 50 years has shown us this.

The last question that Dr Bascom asked was, do we have a local reputation that we don't treat pilonidals so that they go elsewhere? As Dr. Armstrong mentioned, we have a closed population in Hawaii. The patients can't get care elsewhere except if they pay for it. We have not found evidence of this. The patients frequently do come and ask for a definitive procedure, that is, "to cut it out," and sometimes referring doctors who haven't been educated have referred patients for the same thing.

Dr. O'Connell asked about using depilatory agents; we have tried them. Depilatory agents will burn the anal mucous membrane so, in order to use them, you need to protect the anus. Then the depilatory agent is applied, left on for 10 to 15 minutes, and then cleansed off. It works, but I did not feel it offers much value in individual patients. They can't do it themselves because they can't see where they are putting it. In some patients it will cause a rash.

Invited Commentary

The occurrence and treatment of pilonidal sinus disease is neither new nor specifically remarkable. While this study can be criticized from a variety of points of view, its value lies in the distinct focusing of care in this problem on prevention and the shift of treatment from the operating room to the surgery clinic. Although discussion can be advanced regarding analysis of data or prospective or retrospective design, the fact remains that pilonidal sinus disease is a common complaint, relatively poorly addressed in the literature, and responsible for a degree of morbidity considerably out of proportion to the severity of the disease itself. If the type of treatment noted by the authors, based largely on prevention and carried out in the setting of the surgery clinic, could be extended throughout the country, the reduction in morbidity, the savings in cost to the medical system, and the advantages to the individual patients would be incalculable. In my mind, a contribution such as this one, based on sound common sense and extended to the number of patients with this problem, is far more effective than all the current politically correct talk concerning managed care and cost containment in the actual practical reduction of expenditure for medical care in the United States. I believe that this approach, which was first demonstrated to me by Francis Moore, MD, when I was a third year student in the clinics of the Peter Bent Brigham Hospital in Boston, Mass, 40 years ago, merits wide and careful critical evaluation.

Arthur S. McFee, MD
San Antonio, TX