

PILONIDAL SINUS

JOHN BASCOM, M.D., Ph.D.

A major issue in pilonidal disease is, "How extensive should the surgery be?" The question implies a single disease state, but there are at least three. i.e., the acute abscess, the chronic abscess, and the unhealed pilonidal surgical incision. Suggested treatments range from a weekly shave of the involved areas and no surgery to wide excision of the abscess and surrounding tissue down to the sacrum, followed by skin grafting.

But pilonidal disease never requires wide excisions. Pilonidals are abscesses that must be opened. Foreign body reactions that must be cleaned and kept free of new debris. Furthermore, unusual forces pull at a healing pilonidal wound. A surgeon trying to close a pilonidal incision must allow for these forces so that a nonhealing wound, the ultimate in pilonidal problems, is not created.

GOALS OF TREATMENT

Surgeons need a variety of techniques to treat pilonidal disease and must choose those suited to their situation and their patients. Yet it is fair to expect of a pilonidal treatment that it disables a patient for only 1 day, requires minimal postoperative care, heals securely, ensures virtually no recurrence, and is suited to outpatient use.

ETIOLOGY

Pilonidal disease is acquired when gravity pulls the buttocks and cleft from the bone so strongly that skin stretches. Pulling forces that focus between the bottom

of the cleft and the angle of the sacrum stretch the skin. Skin stretches at the bottom of a follicle, where it is thinnest. The stretched follicle breaks down, and an acute or chronic abscess results. Hair is a secondary invader.

PATHOLOGY

Pilonidals are abscess cavities. The earliest stages show variously sized enlarged hair follicles in otherwise normal skin. Each follicle holds a single hair shaft surrounded by rings of keratin. The acute abscess contains pus under pressure and a wall of edematous fat. Polymorphonuclear cells predominate. The chronic abscess has a wall of fibrous tissue lined with brown granulations containing lymphocytes, capillaries, and occasional giant cells. Infiltrating hair appears in half the specimens. Chronic abscesses of long duration begin to receive a thin and flat lining of epithelium, which grows into the cavity from the skin surface. The lining develops no rete pegs and no skin structures. Epithelial tubes or epidermal inclusion cysts may be the result, but they are uncommon. Indolent wounds that fail to heal after surgery resemble chronic abscesses.

CLINICAL PRESENTATION

Patients with pilonidal disease may ask for advice about tiny asymptomatic pits or pores at the bottom of the cleft. Tenderness while doing sit-ups is a common complaint. A tender or nontender nodule may be palpable. One-fifth of such patients seek care for the severe pain and tenderness of an acute abscess. Four-fifths of patients with pilonidal disease present with moisture and drainage and occasional bleeding. They report few or no episodes of pain or tenderness and have no history of a previous acute abscess. Examination shows one to fifteen tiny openings in the midline or a larger granulation-filled slit opening into a cavity. A secondary opening may lie a few centimeters above. Discharge is minimal to copious.

Hairs singly or in tufts often lie in the openings and may be surprisingly long when withdrawn. Unhealed wounds show thin skin that bridges over a cavity or a scarred trench filled with loose granulations.

DIFFERENTIAL DIAGNOSIS

The differential diagnosis should include a boil, hidradenitis, rectal fistula, and perirectal abscess. A deformed and prominent coccyx or a bone spur of the sacrum is often made tender by chronic minor trauma. Removal of the protruding bone is curative.

ALTERNATIVE TREATMENTS

My preferences for treatment are as follows: (1) An acute abscess requires only drainage through an incision to one side of the midline. (2) A chronic abscess is ready for curative closure of the tiny hole in the midline that causes pilonidal disease. A larger cleanout incision to one side of the midline remains open and is allowed to heal from its depths. Healing is prompt, disability minimal, and recurrences rare. (3) For patients referred from elsewhere for treatment of midline incisions that failed to heal, the technique of cleft closure gives excellent results. These preferences were developed during treatment and follow-up of 415 patients with pilonidal disease. Before giving details of those treatments that the author prefers the alternatives are reviewed.

Excision is condemned, since it is the source of most pilonidal complications and disability. Incision that divides but preserves tissue is moderately satisfactory treatment. Excision, however, takes away tissue and can lead to wound tension and trouble. A discouraging sight in pilonidal treatment is the patient with only a long, tiny, unhealed midline wound and retention suture scars to show after years of packing and multiple well-intentioned excisions for benign disease. Ingenious closures have been devised to follow excision, but excision aggravates the very tension that underlies the original pilonidal disease and therefore should not be used.

Antibiotics may resolve some acute abscesses. But if antibiotics fail, the patient suffers unnecessarily until drainage can be started. Antibiotics should not be given to a patient with an acute abscess for a long time until surgery is conveniently scheduled. Antibiotics will not heal a chronic abscess, but they are useful aids to its surgical cure.

Shaving of the area is an effective treatment. A weekly shave heals the chronic pilonidal abscess. Hairs are pulled or brushed from the cavity. Careful cleaning at home is encouraged. In 1987 Barcia reported using shaving for patients with pilonidal disease in the military. This sharply reduced the need for surgery, and unhealed surgical wounds were prevented. The technique demands attention to detail. Do not apply it intermittently or lightly

delegate it to others. Although I personally favor treating pilonidal disease with surgery because of the good results that quickly follow the use of precise techniques, I also strongly recommend shaving alone as a treatment for its simplicity and tissue-saving properties. However, shaving is of no help to the patient with a large unhealed wound.

Simple midline incision is useful treatment despite some disadvantages. It is easily taught, it quickly relieves the pain of an acute abscess, and it is often effective in the case of the chronic abscess. But authors report recurrences and delays in healing after this treatment. Early in my experience I avoided midline incisions as treatment in the fear that I might occasionally create a wound that would never heal. Cleft closure as described below effectively treats that problem, thus making incision a reasonable treatment option. However, I still favor midline closure and open lateral drainage for its quick and secure results. Incision remains the favored treatment for the rare patient with complex branching channels at several levels as a result of long-standing disease. It is best to incise those channels, scrub them, and allow them to granulate in from the base.

The Karydakakis procedure excises an ellipse of skin from one side of the midline along with the abscess cavity and adjacent fat. It avoids the midline closure that can create such difficulty. The concept is sound. My concerns with this procedure include the unnecessary removal of useful fat, the risks of infection associated with primary closure, and the risks of recurrence following reattachment of cleft to sacrum. I have not given the method a trial, but the author claims success with over 5,000 patients.

Unsatisfactory treatments suggested for the unhealed surgical wound include saucerization, packing, and use of Monsel's solution. These treatments require up to 18 months of care. A Z-plasty procedure works, but it mobilizes deep fat and leaves vulnerable suture lines crossing the midline. Rotation flaps are unnecessary. Wide excision with skin grafts is unsatisfactory because it requires a week of hospitalization and leaves a thin and vulnerable surface. All these approaches are replaced by cleft closure, an outpatient procedure that results in only 4 days of disability and virtually no recurrence.

RECOMMENDED TREATMENTS

Acute Abscess

For patient comfort, drain the acute abscess semi-urgently. Do not wait for redness and edema before incising. Thirty minutes before starting, give the patient oral oxycodone hydrochloride (Percocet). Bupivacaine hydrochloride (Marcaine) with epinephrine injected superficially anesthetizes a small area of skin. Blocking of the entire abscess causes unnecessary pain. "Stay out of the ditch," i.e., avoid placing incisions in the midline.

A pointed blade opens a drainage incision parallel to the midline and 2 cm to one side of it. The knife stops when pus first appears. In lieu of packs, which cause pain, excise from one side of the incision a 5-mm circle of skin to prevent premature closure. Antibiotics are unnecessary. Delay further treatment for 1 week, and then treat as a chronic abscess. This delay clears the edema that hides midline holes that must be seen and removed in order to cure the disease.

Relief is immediate. Only rarely does an acute abscess reseal before curative treatment. The advantages of prompt drainage are simplicity, certainty, and quick relief. The only disadvantage is the need for a second procedure.

Chronic Abscess

Four-fifths of patients with pilonidal disease come to the surgeon with a chronic abscess and no history of a prior recognizable acute stage. Chronic abscess patients selected for the treatment outlined below have one to ten holes in the midline occasionally with a larger hole to one side. They are free of acute inflammation. I do not treat asymptomatic patients who have holes that are dry and have never been painful. However, patients who have recently had pain are operated on because a chronic abscess usually lies below the midline. If a short slit is found in the midline, treat it like any other chronic abscess. If the slit is long, treat it like an unhealed incision. Timing of treatment is unimportant.

I use the term chronic pilonidal "abscess" advisedly and avoid the term pilonidal "sinus." The latter term does not distinguish between a tubular chronic abscess that will heal once it is cleaned out and the rare epithelial tube that develops as epithelium grows into a chronic abscess. The epithelial tube is not cured by clean out alone; the epithelium must be excised before the wound will heal.

Start treatment with oxycodone hydrochloride and two oral antibiotics taken 1 hour before the office appointment. I use cephalexin sodium (Keflex), 250 mg, to cover *Staphylococcus* and gram-negative organisms and metronidazole (Flagyl), 250 mg, for the anaerobes that significantly delay pilonidal healing. Infiltrate the skin and deeper tissues with bupivacaine hydrochloride 0.5 percent containing epinephrine to give prolonged comfort and minimize bleeding. Good light and the use of loupes increase precision. A cautery for small bleeders is useful in one case in ten.

Open the chronic abscess widely by a long incision that lies parallel to and 2 cm to one side of the midline. As with the acute abscess, "Stay out of the ditch," i.e., avoid midline incisions. Extend the incision to expose the entire interior of the abscess cavity. Gauze pushed through this long incision scrubs the cavity free of hair and reddish-brown granulations (Fig. 1). For nine in ten patients, leave in place all of the white, fibrous abscess wall. Remove occasional wall segments if they are heavily

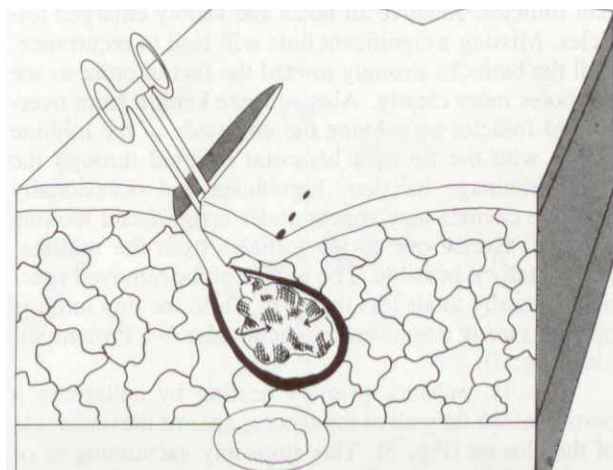


Figure 1 Chronic pilonidal abscess. The most frequent pilonidal problem. This recommended treatment results in only 1 day of disability and recurrence is rare. First, clean out hair and granulations through an incision parallel to the midline.

infiltrated with hair. In a rare patient with long-standing disease, the abscess wall is covered with surface epithelium that has grown into the cavity. This is no longer a chronic abscess but an epithelial inclusion cyst. Remove a 1-mm thickness of that wall. In all cases leave the large lateral incision widely open to permit drainage. Unlike incisions placed in the midline, this lateral incision never fails to heal spontaneously.

Next, "pick all pits," i.e., excise all small holes from the midline skin (Fig. 2). These holes are enlarged

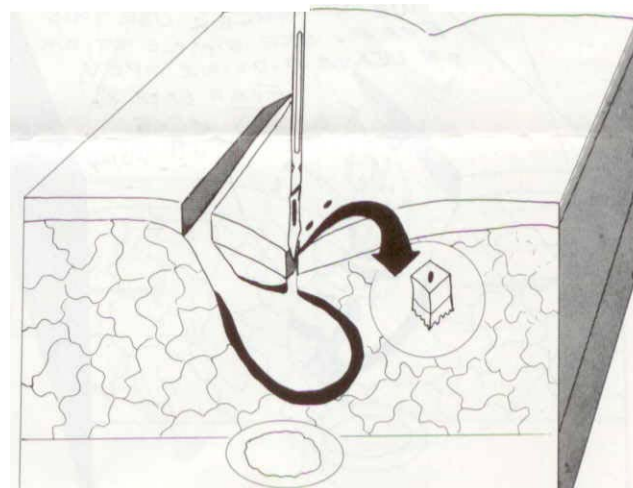


Figure 2 A chronic pilonidal abscess. Remove the hole that creates and sustains these abscesses. The specimen is the size of a grain of rice.

hair follicles. Remove all holes and visibly enlarged follicles. Missing a significant hole will lead to recurrence. Pull the buttocks strongly toward the feet in order to see the holes more clearly. Also squeeze keratin from overlooked follicles by rubbing the underside of the midline firmly with the tip of a hemostat inserted through the lateral drainage incision. Significant and occasionally multiple cavities may appear under insignificant looking follicles. Excise one to ten follicles from the midline, individually if possible. The weight of the removed specimens usually totals less than 1 g. Close the tiny midline openings using a removable subcuticular 4-0 Prolene suture (Fig. 3).

~~Finally, enhance primary healing by collapsing a portion of the far wall of the abscess against the underside of the closure (Fig. 3). This stops any vacuuming in of debris or hair during healing of the midline holes. The loose stitch of Prolene that holds this flap in place is removed at 1 week. Although it is not shown in the drawing, a second tongue of fat from the near wall of the abscess cavity is often collapsed against the floor to provide additional midline fat padding. A single buried stitch of Prolene tacks that in place. JB 8/18/04~~

Continue antibiotics for 24 hours. The patient should shower the wounds daily. No attempt is made to assure sterile dressings. Minipads often suffice. Frequent changes of absorbent cotton will resolve chafing if it appears. The sutures are removed at 1 week and patients should return weekly until the incision is fully healed.

Half the patients return to school or work the next day. For the other half, disability rarely exceeds 4 days. Virtually all these small midline excisions close primarily. Half the larger lateral drainage wounds have closed by 3 weeks. All are closed at 6 weeks.

Complications are rare. Patients on aspirin may

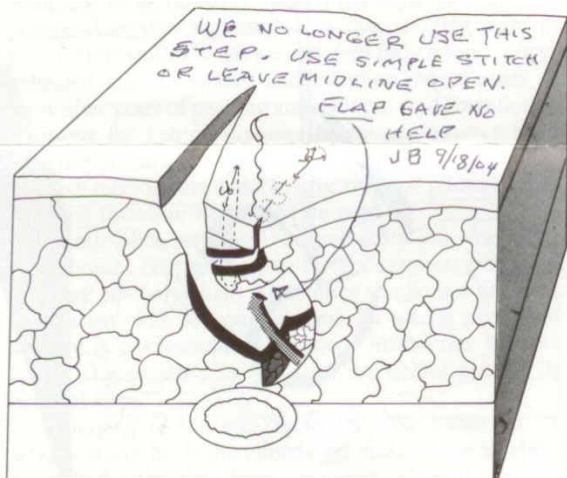

Figure 3 A chronic pilonidal abscess. Leave the lateral wound open to drain, but suture the midline wounds. Reinforce the closure below with fat. This method resulted in no unhealed midline wounds in over 300 patients.

return with bleeding that is controlled by cautery. A tight stitch to the sealing flap may cause necrosis of tissue between the midline and lateral incisions. In this case the wound will heal, but more slowly. In less than 5 percent of cases a midline hole remains open or a new one appears. Heal it with a weekly shave or by daily packing with a bit of cotton, touching it with silver nitrate or picking out and suturing the remaining pit. A rare patient may return years after surgery with an epithelial inclusion cyst somewhere in the area.

The advantages of this approach to the chronic abscess are outpatient treatment, low costs, increased comfort, I-day disability, certainty of healing, minimal aftercare, freedom from unhealed midline wounds and the lowest recurrence rate of any method reported. Patients are never worse as a result of treatment, as opposed to some results obtained with incision or excision.

Disadvantages include some complexity in teaching the procedure and possibly greater expense than treatment by shaving or incision. The method calls for careful, not gross, surgery and richly rewards those who make the effort.

Unhealed Midline Wounds

Last, we consider treatment of the referred patient with a midline incision that has failed to heal after surgery. This was once the most discouraging and disabling problem in pilonidal disease. Better methods now usually prevent its occurrence and have improved its repair, but unfortunately such wounds are still somewhat common. In a personal series of 415 pilonidal patients, I treated 40 patients from other institutions or practitioners whose wounds were still open, often despite multiple previous operations and up to 20 years of disease. The repair that was used is hereinafter referred to as "cleft closure." The basic plan of repair is illustrated in cross-section (Fig. 4).

Patients selected for cleft closure show an open slit at the bottom of the cleft. The cause is usually an unhealed surgical incision. A few long slits develop spontaneously. Timing of this surgery is unimportant and no special preoperative cleaning is needed. Also selected for treatment by cleft closure are some patients without a slit but with many midline holes, especially those with multiple holes at the bottom of a deep cleft that is closely attached to the sacrum.

Cleft closure begins under spinal or general anesthesia with intravenous cefazolin (Ancef) and metronidazole, 500 mg each. With the patient in the jackknife position, examine the area for rectal fistulas, a potent source of failure. Next, push the buttocks together and mark their outer line of contact with a felt tipped pen (Fig 5). After skin preparation and tape retraction, infiltrate the area with bupivacaine and epinephrine to give prolonged postoperative comfort and to limit blood loss (Fig. 6). Sketch the planned incisions on the separated buttocks. Raise a skin flap similar to a mastectomy flap

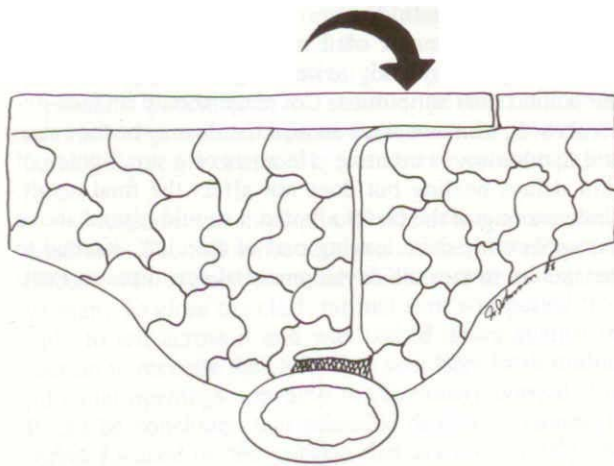
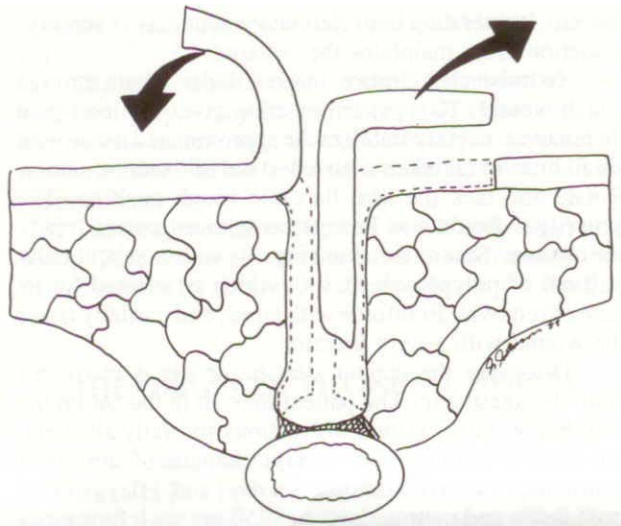


Figure 4 Repair of an unhealed pilonidal incision by cleft closure replaces the defect at the depth of the cleft with a skin flap over a thick pad of fat.

from the least damaged side of the cleft, a full-thickness and fat-free flap. Elevate that skin from the midline out to the previously marked line of natural contact of the buttocks. Undermine the upper end of the cleft to the light dotted line (Fig. 7).

Remove skin on the opposite side. This prepares a surface to receive the flap and unroofs the unhealed wound. Leave the scarred base in place. Scrub away granulations and debris with gauze. Remove any segment infiltrated with hair from the scarred base. Do not mobilize fat or muscle. Save as much tissue as possible to provide padding.

The apex of skin excision (A in Fig. 7) lies above and to one side of the top of the cleft (B). Above the unhealed wound the knife crosses the midline at an acute angle (C). Below it crosses the midline at a right angle (D) to fashion a rotation flap about the anus. The lower

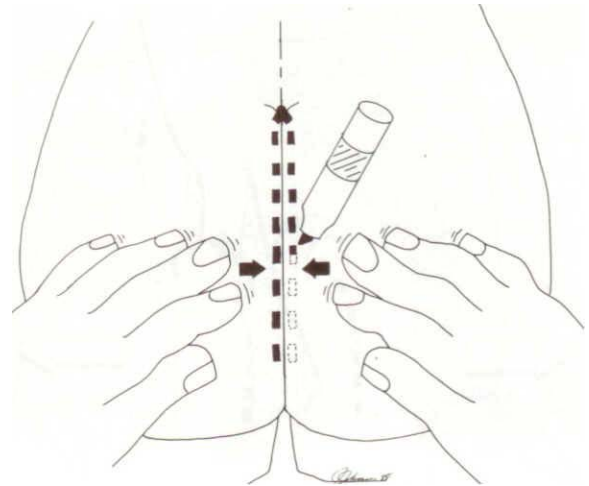


Figure 5 Cleft closure. Note the natural line of contact.

apex of excision is comma-shaped and points toward the anus. Closure along this line avoids tension and resulting skin necrosis at the anal end of the repair. At the end of the sacrum remove skin no farther than the natural line of contact (F in Fig. 8). Removing more skin here risks some postoperative discomfort from skin tension while the patient is sitting.

At this point the raw area is so vast as to cause alarm, but with release of the retracting tapes, the fat falls in from each side. Much of the raw surface disappears, and the elevated flap covers the remainder. Surprisingly, more skin may yet need removal. In order to check, push the buttocks together, and gently pull the upper half of the skin flap across the midline (E in Fig. 8). Remove any skin that is overlapped on the receiving side. Avoid a

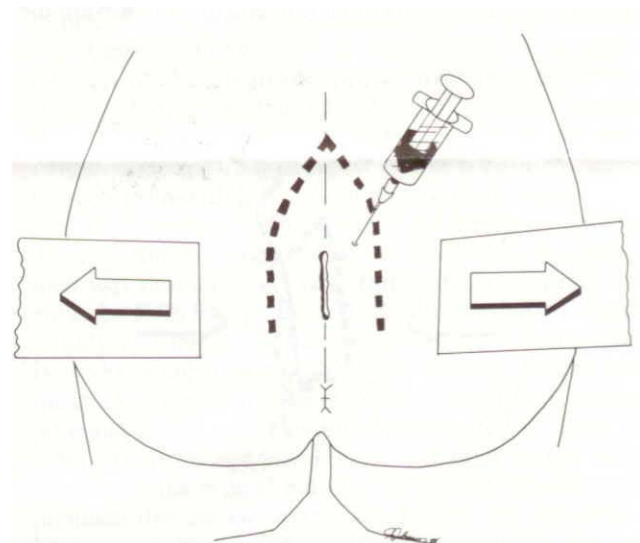


Figure 6 Cleft closure. Tape is used to spread the buttocks in order to expose the unhealed wound. A local anesthetic with epinephrine reduces both operative bleeding and postoperative pain.

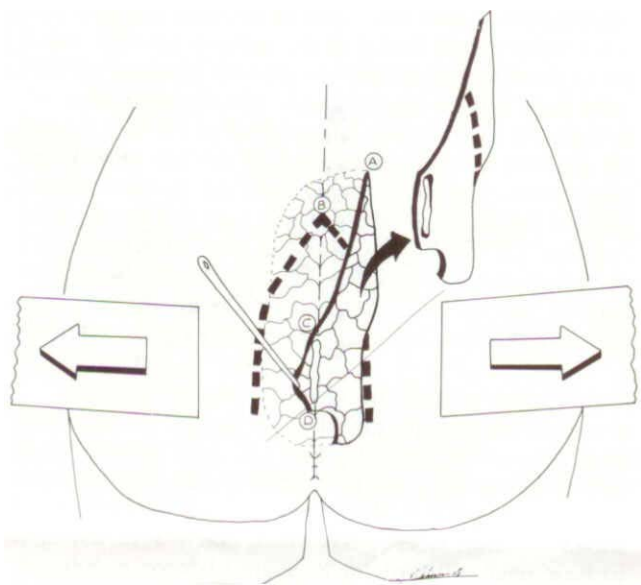


Figure 7 Cleft closure. Mobilize the skin on the left out to the fine dotted line. Remove skin to point (A, which lies above and lateral to the cleft top (B). Cross the midline at an acute angle (C) above the unhealed wound and at a right angle (D) below the wound.

loose flap that folds into the cleft; it may heal poorly because of kinking of the skin vessels.

Difficulty in understanding this repair centers on how to close the perceived "cavity." However, no cavity exists. This is evident on examining a patient who is standing rather than prone. The buttocks fall together, and until pulled apart they hide all disease. Removing 5 mm of skin on each side does not create a cavity. The surgeon's pull separates the buttocks. Release the pull, and the fat falls together and also collapses in toward the

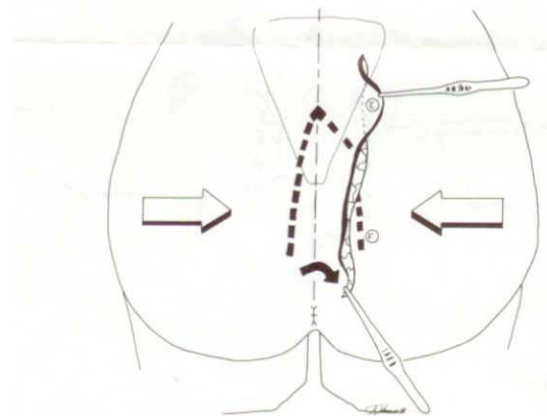


Figure 8 Cleft closure. Release of the tapes allows fat to collapse into the wound. Remove excess skin (E) under the flap in the upper half of the wound. Below the coccyx, preserve skin (F) outside the heavy dotted line to avoid tension when the patient is sitting. Rotate the skin around the anus.

sacrum, obliterating both cleft and wound. After surgery a suction drain maintains the collapse.

To finish cleft closure, insert a Blake drain through a stab wound. That pattern of drain gives the least pain on removal. Lightly stabilize the approximated tissue with small bites in fat taken with a 4-0 polydioxanone suture. Rotate and tack the anal flap into rough position. The skin edges should now lie together without tension, ready for closure. Suture the skin (Fig. 9) with a subcuticular pull-out of polypropylene 3-0, which is selected for its ease of removal. Reinforce with tapes, and partially cover the wound with a light dressing.

Discharge the patient after he or she is recovered from the anesthetic. The patient may sit in the car on the way home. Give written instructions for daily showers, iodophor swabbing twice a day, changes of absorbent cotton near the anus four times a day, and 4 days of oral cephalexin and metronidazole at 250 mg each four times a day. Remove the drain at 4 days and the pull-out suture in 1 week. Examine the wound weekly until healing is complete. Most patients are able to resume regular activities on the fourth day.

Complications of cleft closure are infrequent. Infection responds quickly to opening the inferior 2 cm of the wound plus antibiotics. Coverage should include anaerobes. In resistant cases an anal fistula may be the cause and fistulotomy is curative. Necrosis of a small patch of skin delays healing but does not affect the final result. Undermining of the cleft to flatten it should extend above the upper end, since leaving part of the cleft attached to the sacrum invites the development of new disease. Post-

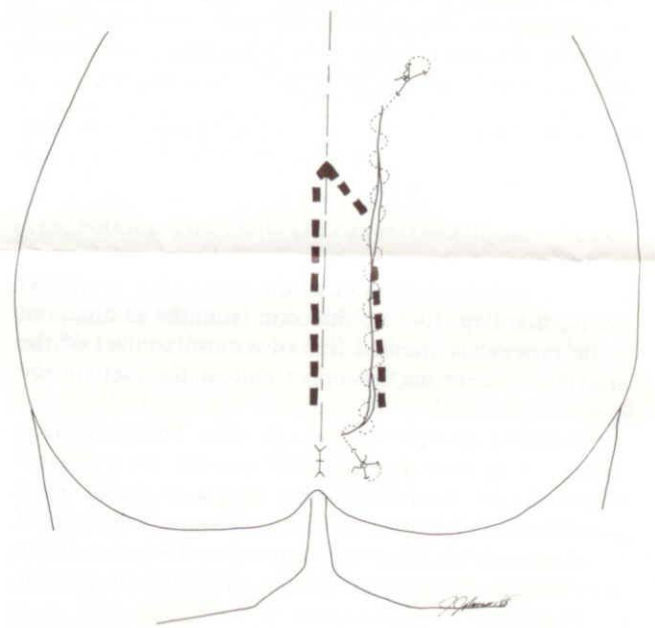


Figure 9 Cleft closure. Suture without tension. A lifting thread tied around the middle of the monofilament simplifies removal. This outpatient repair on 40 patients who had wounds open up to 20 years has resulted in 4-day disability and secure healing.

operative discomfort on sitting is rare and largely avoidable.

The marked advantages of cleft closure include outpatient surgery, 4-day disability, certainty of healing, and virtually no recurrences. Complications, unlike those after re-excision, do not create a problem greater than the original one.

The disadvantage is the need for a hospital operating room. Cleft closure is extensive surgery and requires more than is needed for surgery for the simple chronic abscess.

THE ORIGIN OF PILONIDAL DISEASE

What causes pilonidal disease? Part of the answer is midline holes. Every pilonidal abscess can be traced to one of these holes. The microscope shows that these holes seem to be hair follicles that have enlarged. Enlargement seems to be caused by a pulling force between sacrum and skin. That pull appears when gravity drags heavy flesh away from a corner of bone. In 1969 Brearly found the pull and measured the vacuum it creates. One can see signs of the force when looking at the hole while a pilonidal patient is in the standing position. Close attention to the cleft of a prone patient while pushing the buttocks strongly toward the feet also reveals the pulling force.

pilonidals are an acquired rather than a congenital condition. The following case exemplifies this. pilonidal disease was excised from the midline skin of a young woman. To close the cleft, normal skin was pulled from right to left across it and was tacked down against the sacrum to recreate the cleft. One year later fresh midline pilonidal openings appeared in previously normal skin. It can be concluded that pilonidal disease is caused by forces focused on the midline that act on *any* skin that happens to be located there and not by a congenital defect of midline skin itself.

Since this concept of focused midline forces is an unfamiliar one, another description may be helpful. Forces give rise to very high tensions when concentrated in a small area. It seems a paradox that a 1 g phonograph needle exerts a pressure of 2,000 lb per square inch. The apparent paradox is explained by the small fraction of a square inch involved. In pilonidal disease, tension forces are similarly focused in a small area.

Nature seems to "glue" midline skin to the coccyx. When the skeleton stands erect, heavy skin dangles from the coccyx, folding into a deep crease. The skin of the crease is pulled away from bone by gravity. Forces concentrate in a 1-mm² area where the narrow gluteal crease comes closest to the sharp angle at the lowest end of the sacrum, where the coccyx turns anteriorly. Measurements of the position of pilonidal holes in relation to the sacrococcygeal angle in 25 patients showed that the primary hole almost always appears at that point (Fig. 10).

Forces pulling on the dermis increase with bouncing activity while the individual is upright or with slumping while the individual is sitting. Bouncing on hard seats

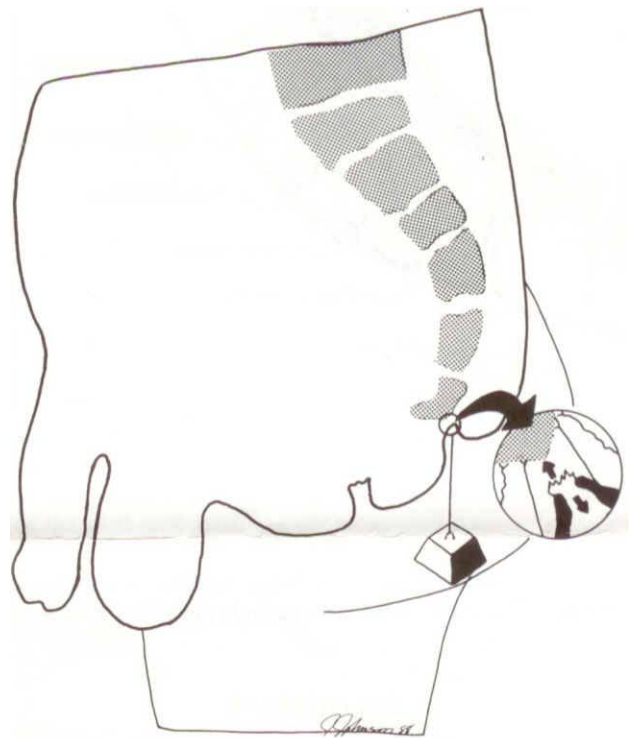


Figure 10 The origin of pilonidal disease. The dangling block in the diagram suggests the weight of the buttocks as they pull skin away from the sacral angle. If skin tears under tension at its thinnest point, i.e., at the bottom of a follicle as shown in the circle, a pilonidal abscess results. Examine a standing patient to see this zone of tension.

as in a jeep or tank, further increases such forces. If forces become intense enough, something gives way. The weakest point gives way first, and skin is weakest where it is thinnest (inset in Fig. 10), i.e., at the bottom of the follicle. This seems the most satisfactory explanation for the observed enlargement of follicles and the constant location of the pilonidal opening over the end of the sacrum. A diagram shows the stages of pilonidal disease (Fig. 11). Notice that edema closes and hides the pore in folliculitis and the acute abscess. The pore often cannot be seen even with bright light and magnification.

Hair shafts are often blamed for creating pilonidal disease. Authors suggest that the shafts drill or burrow their way through intact skin. But evidence suggests that enlarged follicles appear first. Significant hair is found in only half the cases, but pits are found in every case. Hair shafts are important, for they prolong disease and interfere with healing. The ingestion of hair by an existing pilonidal cavity was cleverly demonstrated by Page in 1969. An unwashed young male with thick hair is often considered the typical patient, but half of patients with pilonidal disease are women, and many are fastidious. Hair is probably an important secondary invader but not the usual primary source of a pilonidal abscess.

pilonidal disease appears only in young adults, who as a group have moist skin under youthful tension and adult-sized buttocks. A pilonidal abscess only appears

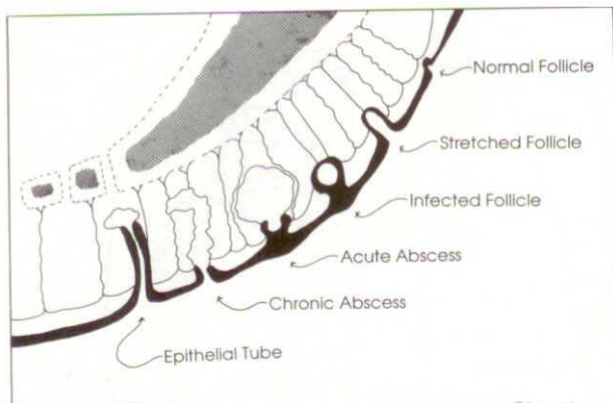


Figure 11 Probable natural progression of pilonidal disease. Edema hides the mouths of the infected follicle and the acute abscess.

when the pull is strong enough and midline skin is weak enough. The pull sucks keratin and often hair into subcutaneous tissue, thus starting the abscess. pilonidal disease persists until the inflammation-producing material is removed from the cavity and the hole that permitted entry is permanently closed.

Why does the follicle removal method as described above control the disease? I assume because the scarring of the dermis after surgery toughens it sufficiently to prevent enlargement of adjacent follicles. Further, fat rolled under the closure disconnects skin from bone, distributes the pull, and decreases tension on skin.

SUGGESTED READING

- Bascom JU. Repeat pilonidal operations. Am J Surg 1987; 154:118.
 Brearly R. pilonidal sinus: A new theory of origin. Br J Surg 1969 13:62-67.
 Klass AA. The so-called pilonidal sinus. Can Med Assoc J 1956: 75:737
 Page BH. The entry of hair into a pilonidal sinus. Br J Surg 1969; 56,32.

Current Therapy in Colon and Rectal Surgery
 ISBN 1-55664-043-9

Notes added by John Bascom:

AUTHOR'S UPDATE: 8/8/04

I re- examined this article after fourteen years. In my further experience the concepts and treatments work well. To simplify the chronic abscess treatment by "pick pits and lateral drainage", called by some the "Bascom I operation", we no longer use the flap of Figure 3 as described on Page 4.

The operation for unhealed midline wounds, which some call the "Bascom II operation", I now call "cleft lift" to reassure patients who feared that surgery would completely eliminate the cleft and leave them deformed.

Details in my description of cleft lift in Figure 8 confused some readers particularly in regard to skin near the anus. Surgery extends that far distally in only in the most extreme of cases. Confusion clears for some readers when they studied illustrations in the article from Arch Surg 137:1145 2002 which is posted on this web site. Other materials from this web site may be of further help.