

Quick Tutorial on the Bascom Pit-Picking Technique:

We are working from the concept all Pilonidal abscesses are caused by pits, by 'zits' that rupture into deep fat at the bottom ("the ditch") of the cleft, zits that form when bones stand but buttocks drag toward the floor and pull of buttocks creates forces that stretch hair follicles. The "pits" in the midline are the source of the abscess cavity more commonly known as Pilonidal. Removal of the source of the abscess (the pits) generally will resolve Pilonidal without excision of the tissue.

Picking Pits -

(See the pictures that follow for more detail) Excise all holes from the midline skin, these holes are enlarged hair follicles. Remove all holes and visibly enlarged follicles. Missing a significant hole will lead to recurrence. Pull the buttocks strongly toward the feet in order to see the holes more clearly. Also squeeze keratin from overlooked follicles by rubbing the underside of the midline firmly with the tip of a hemostat inserted through the lateral drainage incision. Significant and occasionally multiple cavities may appear under insignificant looking follicles. Excise one to ten follicles from the midline, individually if possible. The weight of the removed specimens usually totals less than 1 g. Close the tiny midline openings using a removable subcuticular 4-0 Prolene suture.

When presented with an acute abscess, our technique is to drain the abscess laterally, a finger's width off the midline (STAY OUT OF THE DITCH!) Once the abscess is open, drained and scrubbed out, we send the patient home for 10 days for edema to fade – we do not pack the abscess. When the patient with the drained abscess returns to the office, the edema will have cleared and the pits will be easily visible by pulling the midline skin towards the feet. We then excise all pits from the midline.

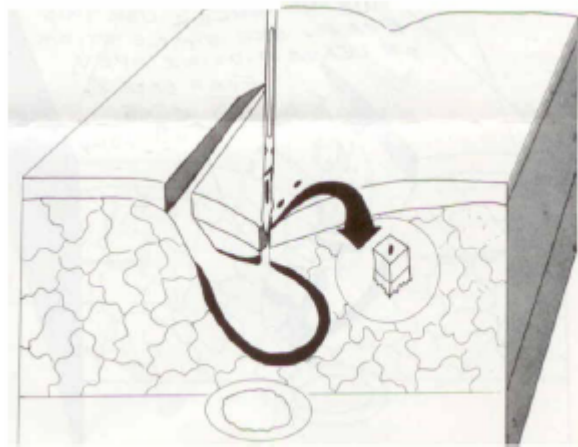


Figure 2 A chronic pilonidal abscess. Remove the hole that creates and sustains these abscesses. The specimen is the size of a grain of rice.

Pictorial Guide

Pictures 1 - 5 are the same person, a youth with a slightly tender nodule over the sacrum. Note the minimal body hair. But note that in 1) the hands pull the skin toward the feet. This makes the pits show clearly. They were nearly invisible in 5). The pits are easily missed without the pull.

This demonstration of the way a pull on skin enlarges pits gives a hint of the way the same pull creates the pits and enlarges them. The weight of the buttocks pulls skin away from sacrum in a standing patient. All that keeps the buttocks from falling into our socks is a narrow line of attachment to the tip of the tailbone. If the pull grows strong enough, something will give way. The weakest point which gives way is skin where it is thinnest, at the bottom of a hair follicle. Or skin where a hair drills in to thin it, where skin is thinnest at the bottom of the drill hole.

The continued pull tends to enlarge the pits and pull in hairs that may lie in the cleft, thanks to barbed the scales on hairs which act like barbs on a fishhook. Hairs, as seen from a skin cell on the side of the cleft, loose hairs brush by. But as seem from a skin cell in the bottom of the cleft, loose hairs come like a railroad train; end on and driving.

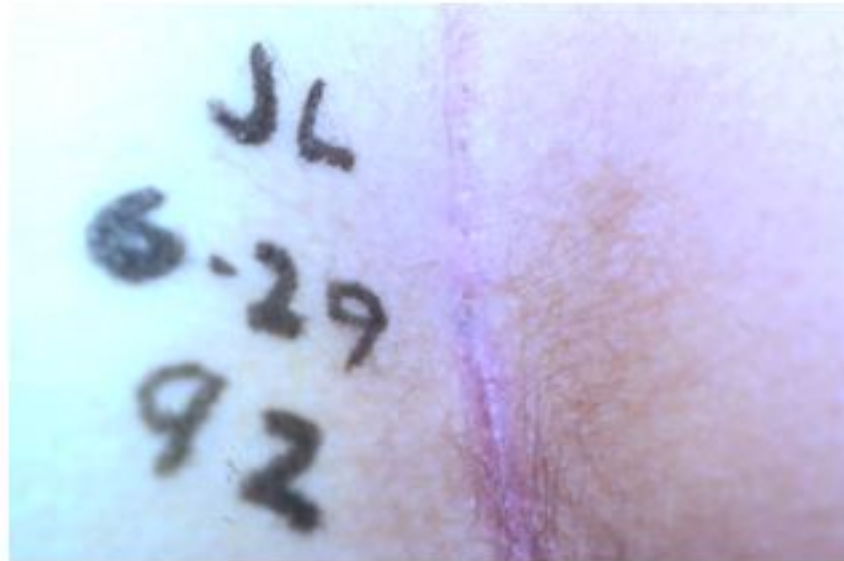Look at pits in a standing patient. Contrast that view with the view of pits on a patient supine on an exam table.

An abscess starts in fat once skin germs invade fat, sneaking in through the pinhole at the bottom of a pit.

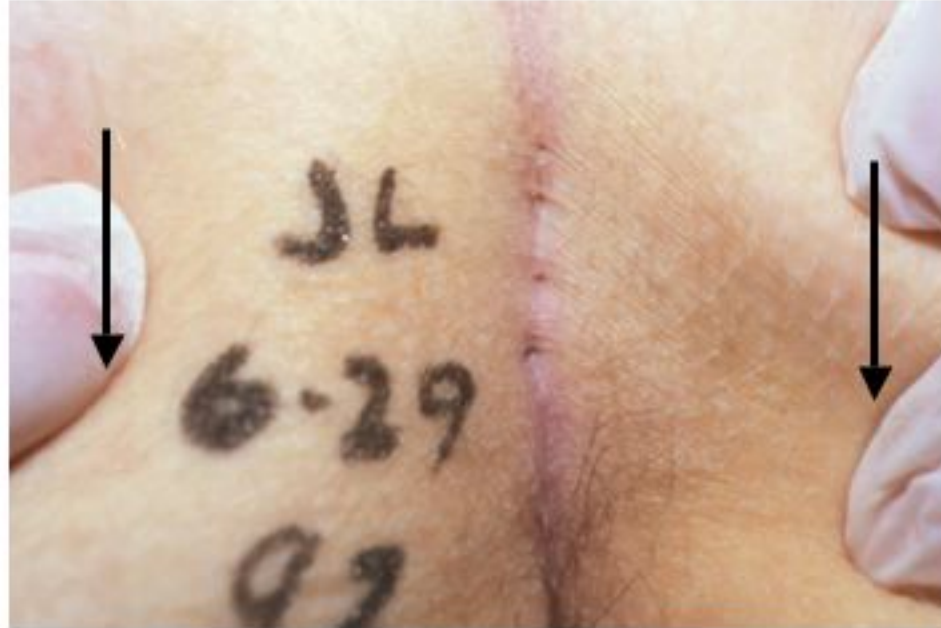Close the pit to stop the disease. Usually we have to empty the abscess also.

Picture 6 -

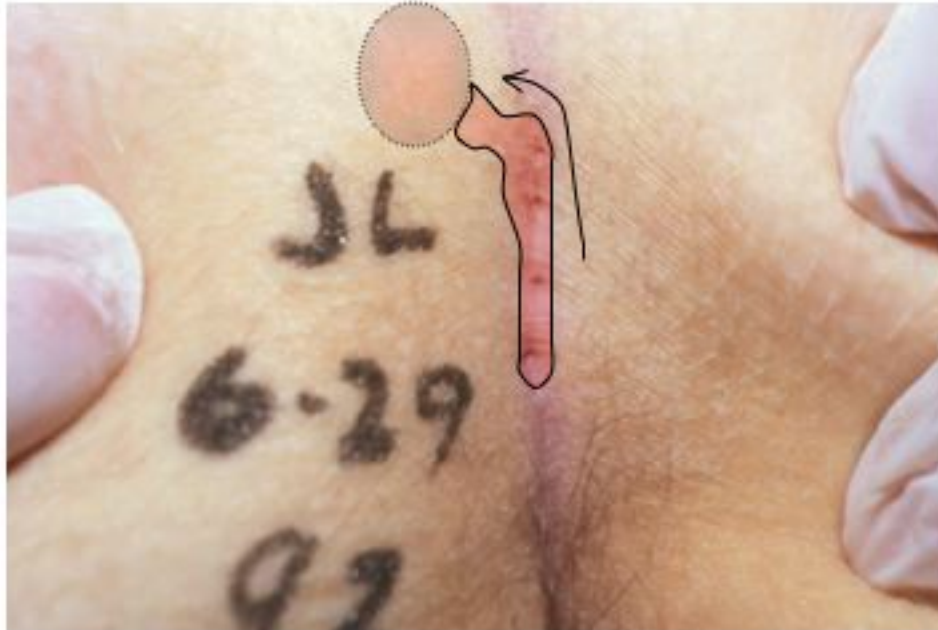One week after pick pits and stay out of the ditch. The small stitches are ready for removal from pits removal. The non-tender healing wound will be closed in 2 weeks. Keep the site clean with BabyWipes four times a day followed by Betadine-wet gauze for a minute in addition to twice a day showers.



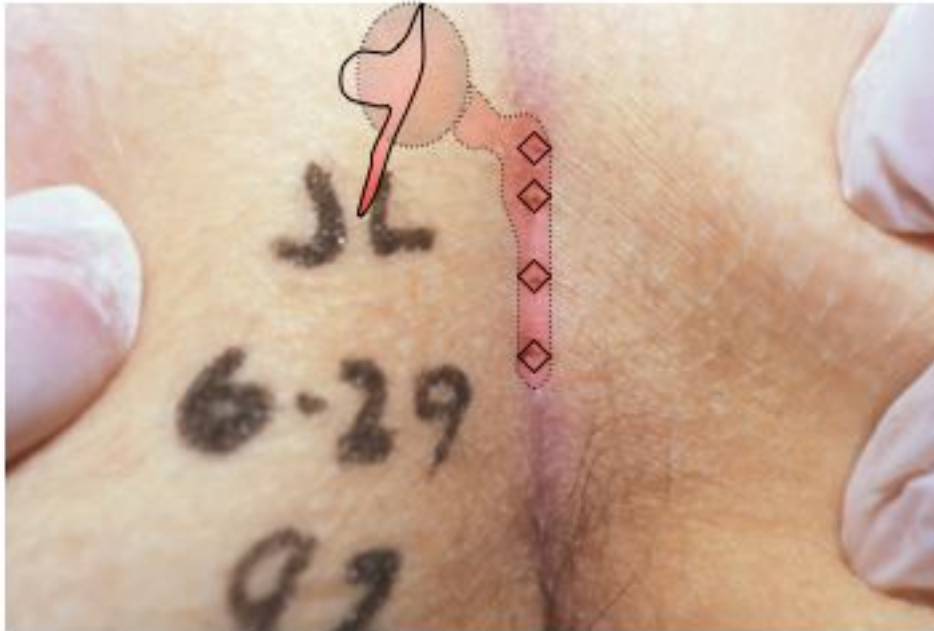This patient found a nodule under midline skin. We suspected it was a chronic pilonidal abscess. Our first look showed no pits. Pits are the pinholes that start all pilonidal trouble. To find a pit is a sure sign that the nodule is a pilonidal abscess.



Same patient, different light. We pulled skin down toward the feet to reveal four pits.

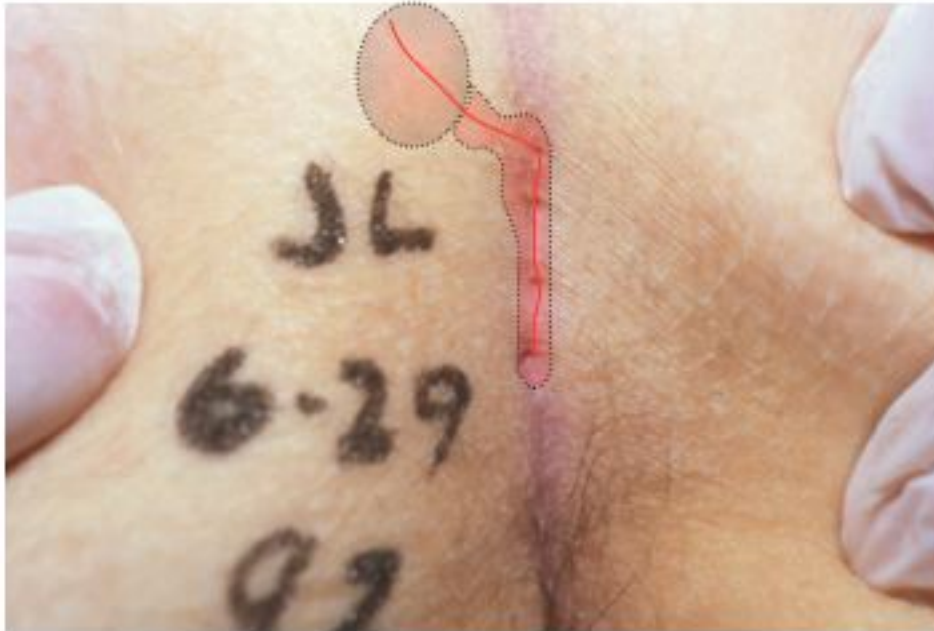

Path of infection from pits to chronic abscess



Treatment option #1. Pick all pits (Excise each enlarged hair follicle.) Stay out of the ditch. (Place drainage incision over abscess but lateral to midline.) Scrub out all cavities.

Most of early patients can be treated as outpatients under local anesthetic. Side incisions heal 100%.

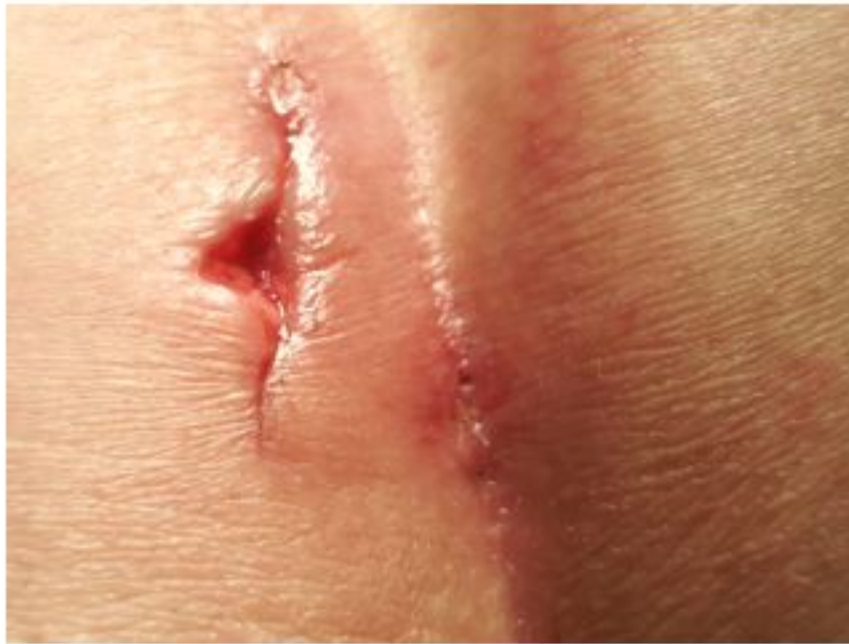

Treatment option #2. Simplest option. Cut on red line through all pits and across the abscess cavity. Scrub the lining clean. Keep the cleft clean and allow incision to heal. This will cure ~ 80% of cases and never produce large unhealed wounds.

If small part of wound fails to close in 3-6 weeks, then cleft lift is a good option.

Avoid midline sutures or packing and wide EXCISION!

Some MDs favor sewing skin edges to bottom of abscess, “marsupialization”, but NOT to presacral fascia. Some fill with fibrin glue.



Post-op 2 days in a different patient. We had picked a single pit out of the midline and closed it with a single stitch of monofilament, the stitch to be removed at one week. In this photo on the second postoperative day the stitch is barely visible. The apparent pit in the midline is a gap in the wound that we expect will heal.

We had opened the abscess cavity with a lateral incision. The extra skin removed from the left edge permitted free drainage if necessary. It was used to prevent premature closure of the rapidly healing incision. We removed most of hair and scrubbed granulation tissue through this wound.

On the day after office surgery under local anesthetic the patient drove 200 miles without needing pain pills.