

# Pilonidal Disease: A Conservative Treatment

**Misunderstood therefore overtreated; when understood treated simply**

James H. Pingree, MD, FACS  
Cottonwood Surgical Associates  
166 E. 5900 S. Suite B-1 03  
Murray, UT 84107

## Introduction

Pilonidal Disease (PD) is a widely misunderstood entity. Overzealous treatment often leads to a problem which is far worse than the initial condition -- that of an open, weeping, midline wound that remains unhealed, or at best takes many months to heal by secondary intention requiring daily packing and other care.

The misunderstanding came about because it was believed that PD was possibly a congenital process and a true cyst because of the hair commonly found in the diseased tissues. However, it has been ascertained that PD is not a cyst, but is an abscess caused by bacteria entering the subcutaneous tissues through diseased hair follicles in the midline of the cleft between the buttocks. (1) These follicles become enlarged due to midline vacuum and

pulling forces. They are identified in asymptomatic patients by a pinhead-sized opening often called a "pit." Sometimes individuals will have

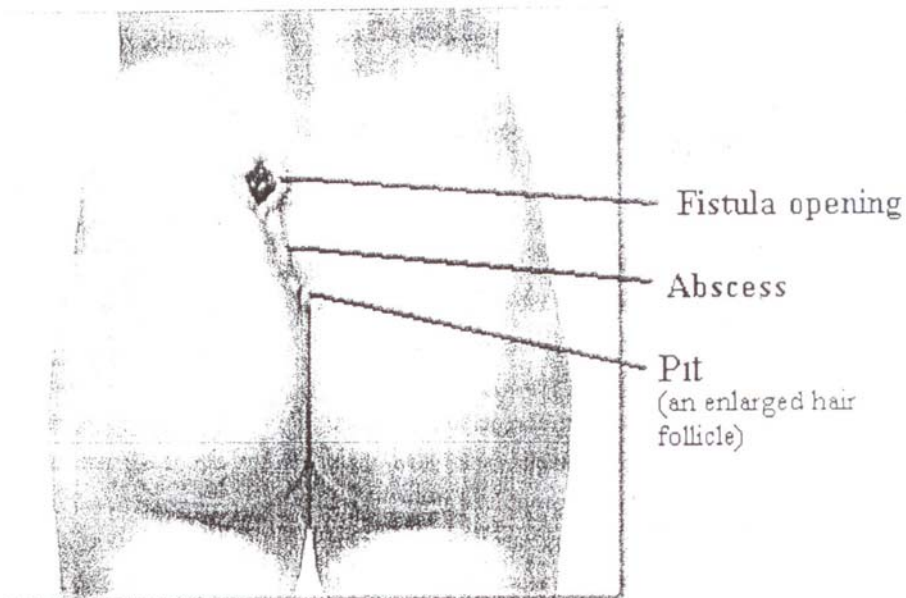
multiple pits in the midline of which they are totally unaware. Bacteria can then enter through the pits into the subcutaneous tissue creating an infection and often abscess formation. (See Figure 1.) Many times hair shafts are sucked down into the subcutaneous tissue through these pits.

Because of the mistaken belief that this disease was a true cyst, surgeons have often attempted to "cure" it by

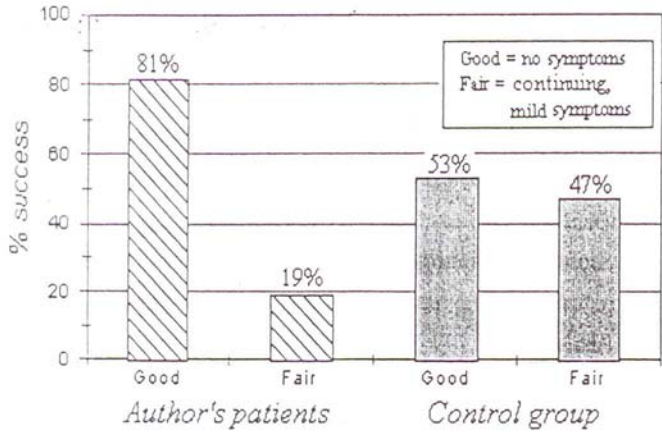
wide excision, and either: 1) attempt to close the wound in the midline, which type of incision is notorious for not healing well; or 2) leave the wound open to heal by secondary intention, a very prolonged process. After treatment, the patient was then left with a far more serious situation.

Knowing that PD is nothing more than a subcutaneous abscess, which began because of midline pit formation, a rational method of treatment can be formulated. In most instances a "conservative" treatment can be utilized to *control* the process rather than immediately attempting to *cure* it by surgical excision. This is intuitive because PD is rarely seen after the age of thirty and therefore will usually resolve itself if it can be controlled until that time. (2)

**Figure 1:** Pilonidal disease is caused initially by an enlarged hair follicle in the intergluteal cleft, through which bacteria can enter the subcutaneous tissue causing an abscess. A fistula may also develop.



**Figure 2:** This graph shows the success rate of conservative treatments. There were no patients who did not achieve control of the disease from conservative treatment in the author's group. The difference in a "good" success rate between the author's patients and the control group is attributed to the level of instruction given to the patient about how to control the disease.



**Patients and Methods**

In order to ascertain the validity of utilizing conservative therapy rather than radical excisional surgery, this study was comprised of 83 male and 15 female patients. The author's fifty patients received a trial of conservative therapy unless the patient chose otherwise or excisional surgery had been performed that remained unhealed. The remaining 48 patients of other physicians constitute the control group.

The study had a duration of 33 months. Follow-up was obtained by survey forms, telephone calls, or office visits. Those in the study for less than 6 months were not included in the results.

**Results**

The discussion of the study results can be divided into data about two patient groups: 1) those patients treated by the author, and 2) the control group treated by other physicians throughout the United States.

*Treatment by the author.* The author treated 50 patients with conservative treatment, and gave them instruction; 81% had a "good" result and 19% had a "fair" result. (In terms of success rate, "good" means having no subsequent symptoms, or satisfactory control

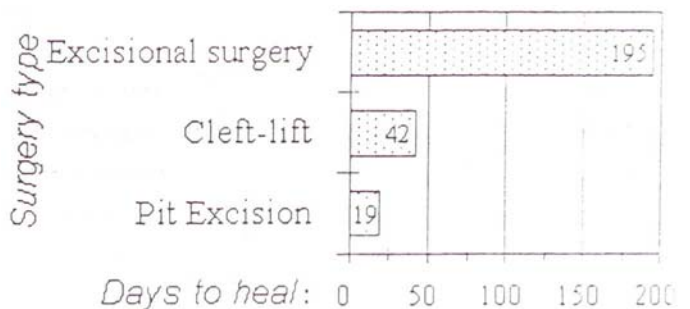of the disease. "Fair" means having continued mild symptoms such as discomfort or discharge.) All of the patients with a "good" result are now asymptomatic. Of this group, about half had no problems after the initial treatment, one-fourth had minimal symptoms that required no further attention, and a final one-fourth had symptoms that required another office appointment for further, simple, conservative treatment. Lastly, none of the patients with a "fair" result had symptoms severe enough to warrant surgery.

Five patients elected to have non-conservative treatment. Four patients had removal of midline pits and lateral drainage, which healed completely within an average 19 days. One patient received the Clef-lift procedure (discussed below) because of an unhealed wound from a previous excisional surgery.

*Control Group.* This group consists of 19 patients who received conservative treatment and 29 patients who had excisional surgery. Since these patients were treated by other physicians, the level of instruction; they received is unknown, and likely minimal. About half of those receiving conservative treatment have had "good" result with no further symptoms since treatment. The other half are still having minimal symptoms, indicating a "fair" result. See Figure 2.

Most patients treated with excisional surgery healed (79%), but in an average 6.4 months with daily wound packing, and a significant rate of recurrence (27%). The remaining excisional surgery patients still have unhealed wounds (21%). See Figure 3.

**Figure 3.** Average Healing time for three surgical procedures as treatment for Pilonidal Disease in this study. Excisional surgery not only has a high rate of recurrence, it often leaves a wound which never heals. In this study, 27% of the excisional surgery patients had a recurrence of the disease, and 21% remain unhealed. Surgery a treatment of PD should only be performed when necessary, after a trial of conservative treatment has failed to provide satisfactory control of the disease.



## Discussion

This section will describe an algorithm for successful PD treatment, also represented graphically in Figure 4.

In asymptomatic individuals that are found to have small midline pits nothing more should be done than to educate them to use good hygiene-- thorough cleaning and drying after each shower or bath and wiping forward after a bowel movement rather than backward. (If bacteria can be kept from gathering about the opening of the pits, then infection is unlikely to ensue.) Also, the patient should avoid traumatizing the area with such activities as excessive bicycle riding and improper sitting (not sitting straight). These activities keep the pits open; allow more bacteria to accumulate, and hair shafts to penetrate the pits. The hair shafts may also penetrate any thin skin that may have closed off the pits, allowing bacteria and/or the hair shaft to enter the subcutaneous tissue.

If the patient is symptomatic with an acute abscess formation, nothing more should be done except to incise and drain the abscess placing the incision away from the midline, pulling any hair shafts protruding from the pits, prescribing antibiotics, and sitz baths. Shaving the intergluteal cleft seems to be very beneficial. Occasionally silver nitrate or phenol can be used to eliminate granulation tissue to help close the abscess cavity and fistula tracts, if present. The openings of the fistulas should be debrided to allow better access for treatment with these agents. When the patient again becomes asymptomatic the use of good hygiene often prevents further episodes.

If the condition is recurrent in spite of good hygiene, a simple operation of excising and closing the small midline pits and cleaning out the abscess cavity through a lateral incision will often be curative. (3) This can be done with local anesthetic in an office setting.

If the condition fails to improve after the above steps or if the patient has had previous excisional surgery, which failed and was therefore left with a chronically open wound, the Cleft-lift procedure is recommended

(4,5,6) This procedure obliterates the deep cleft, which allowed the PD to develop and the non-healing to occur. It also creates an environment where the disease will not recur. The incision for this Cleft-lift operation falls not in the midline but to the side. This can generally be done as an outpatient procedure.

Both pit excision and the Cleft-lift procedure have significantly shorter healing times than excisional surgery. See Figure 3.

## Conclusions

1. All patients should have a trial of conservative treatment as it will eliminate all symptoms in 8 of 10 cases if the patient is properly instructed and practices good hygiene (Figure I).
2. If conservative treatment is insufficient, pit excision or the Cleft-lift procedure should be performed.
3. Excisional surgery has no role in treatment.
4. Control, not curing, is the goal in successful treatment of PD.

## References

1. *Pilonidal Disease: Origin from Follicles of Hairs and Results of Follicle Removal as Treatment.* John Bascom Surg. 1980;87:567-572.
2. *Pilonidal Sinus Disease - The Conservative Approach* John H. Armstrong MD; Peter J. Barcia ,MD Archives of Surgery, 129:917, Sept. 1994.
3. *Pilonidal Disease: Long-term Results of Follicle Removal.* John U. Bascom, MD. Diseases of the Colon & Rectum, 26:800-807, Dec. 1983.
4. *Repeat Pilonidal Operations:* John U. Bascom. MD, PhD. The American Journal of Surgery, 154: 118-122. July 1987.
5. *Pilonidal Sinus.* John Bascom, MD. PhD. Current Therapy in Colon and Rectal Surgery, Victor Fazio, MD, Editor. B.C. Decker, Inc. Pps. 32-39: ] 990.
6. *Pilonidal Sinus.* J.U. Bascom, MD, PhD. Current Practice in Surgery. Vol. 6, Pps. 175-180