

AQUACEL[®] Ag DRESSINGS **made easy**

Volume 2 | Issue 2 | May 2011 www.woundsinternational.com



Introduction

AQUACEL[®] Ag dressings (Box 1) incorporate Hydrofiber[®] Technology with 1.2% (w/w) silver (ie 12mg of silver per gram of dressing). The combination of Hydrofiber[®] Technology with ionic silver (Ag⁺) produces a dressing that is highly absorbent, has favourable gelling characteristics (Box 2) and broad-spectrum antimicrobial activity (as demonstrated by *in vitro* testing)¹⁻³. These qualities mean that AQUACEL[®] Ag dressings can assist in overcoming major challenges to wound healing.

Authors: Queen D, Walker M, Parsons D, Rondas A. Full author details are on page 6.

What are AQUACEL[®] Ag dressings?

AQUACEL[®] Ag is a versatile primary dressing indicated for moderate to highly exuding chronic and acute wounds where there is infection or an increased risk of infection. AQUACEL[®] Ag Ribbon Dressing with Strengthening Fiber is suitable for cavity wounds and AQUACEL[®] Ag SURGICAL cover dressing is used on surgical incisions (Box 1).

How are AQUACEL[®] Ag dressings made?

AQUACEL[®] Ag dressings are made using patented Hydrofiber[®] Technology processes (Box 2). The even distribution of ionic silver permits antimicrobial activity; while the silver deeper within the dressing acts as a reservoir to provide sustained silver availability^{3,4}.

AQUACEL[®] Ag Ribbon Dressing with Strengthening Fiber is made from strips of silver impregnated Hydrofiber[®] Technology that have been stitch-bonded with a non-gelling yarn. The yarn reinforces the ribbon dressing to provide tensile strength even when the dressing is wet.

AQUACEL[®] Ag SURGICAL cover dressing is made by layering an island of silver-impregnated Hydrofiber[®] Technology with a hydrocolloid adhesive layer and a breathable polyurethane film backing. The Hydrofiber[®] island is stitch-bonded with nylon and elastane yarns to provide more flexibility if the dressing is placed over joints. The hydrocolloid layer allows adhesion to the skin and the polyurethane film acts as a waterproof bacterial barrier.

Managing exudate

A key feature of dressings made with Hydrofiber[®] Technology is their ability to lock in any fluid that is absorbed⁵ (Box 2). This means that wound exudate, and the pathogenic bacteria and

Box 1 AQUACEL[®] Ag Dressings

Dressing name	Format and uses
AQUACEL [®] Ag Dressing	Flat sheet of varying sizes for acute and chronic wounds
AQUACEL [®] Ag Ribbon Dressing with Strengthening Fiber	Ribbon for packing deep wounds, cavities and tunnels; reinforced with strengthening fibers to provide excellent wet tensile strength
AQUACEL [®] Ag SURGICAL cover dressing	Flat sheet backed with a hydrocolloid adhesive layer and polyurethane film for use on surgical incisions

harmful enzymes that it may contain^{6,11}, are removed from the wound bed. As a result, the wound surface and surrounding skin are protected from potentially harmful effects^{9,10}. In addition, when the dressing is removed from the wound, the trapped bacteria and enzymes are also removed, meaning that any release of bacteria from the dressing into the air is minimised.

In acute healing wounds and in chronic wounds, dressings made with Hydrofiber[®] Technology maintain a moist wound environment whilst absorbing excess exudate¹². In partial thickness wounds (eg burns), animal studies have shown that neutrophils are taken up into dressings containing Hydrofiber[®] Technology and a layer of fibrin forms between the dressing and the wound⁷. The fibrin aids adhesion of the dressing to the wound, enhancing conformability and reducing dead space. In addition, the uptake of neutrophils into the dressing in combination with the fibrin layer may prevent interaction of these immune cells with macrophages and so reduce the inflammatory response⁷.

Antimicrobial properties

AQUACEL[®] Ag dressings contain ionic silver and provide sustained and effective antimicrobial activity against a wide range of aerobic, anaerobic (including antibiotic resistant strains such as methicillin-resistant *Staphylococcus aureus* [MRSA] and vancomycin-resistant *enterococci* [VRE]), yeast and filamentous fungi for up to 14 days, as demonstrated by *in vitro* testing^{3,13}. AQUACEL[®] Ag dressings may be left in place for up to seven days in chronic wounds¹⁴ or for up to 14 days on partial thickness burns¹³. The ionic silver in AQUACEL[®] Ag dressing starts killing a broad spectrum of pathogens, including MRSA, within 30 minutes of exposure to the dressing³. In addition, bacteria absorbed into the dressing are also destroyed^{1,15}. AQUACEL[®] Ag dressings also control bioburden by micro-contouring to the wound bed (Box 2) to prevent dead spaces where bacteria may flourish and to ensure delivery of the antimicrobial ionic silver directly where needed (as demonstrated by *in vitro* testing).

AQUACEL[®] Ag DRESSINGS **made easy**



Box 2 What is Hydrofiber[®] Technology?

Hydrofiber[®] Technology is a patented technology by which fine fibers of high-purity cellulose are carboxymethylated in a very controlled way. Carboxymethylation of the cellulose alters its structure to allow it to better absorb and retain fluid. The fibers are meshed together by needle-bonding. This process uses fine barbed needles pushed through the fibers to entangle them to form a stable fleece layer. The layer can then be cut to form dressing pads or ribbons.

Locking in fluid

Dressings that contain Hydrofiber[®] Technology rapidly absorb fluid⁵. Once fluid is absorbed, the fibers swell to form a clear, soft, cohesive gel that is able to retain structural integrity (Figure 1) and maintain a moist wound environment to support healing. As the fibers swell, the fluid and its contents, eg bacteria, inflammatory cells and enzymes, are trapped and held within the dressing^{6,7}. In addition, the gelling action prevents lateral spread of fluid through the dressing, reducing the risk of periwound maceration⁸⁻¹⁰.

Micro-contouring

Dressings that contain Hydrofiber[®] Technology have the ability to closely contour (micro-contour) to the wound bed when a gel forms¹ (Figure 2). This means that there is no or very little dead space between the wound and the dressing⁷ where fluid may accumulate and bacteria may proliferate (as demonstrated by *in vitro* testing).

Responding to wound conditions

Dressings that contain Hydrofiber[®] Technology are able to respond to wound conditions by forming a cohesive gel. The gelled dressing maintains a moist wound environment, aids autolytic debridement and supports the healing process. At dressing removal, the gelled dressing does not damage delicate granulation tissue or the healthy tissue surrounding wounds.

Because the silver ions are readily available and easily dissociated from the strands of Hydrofiber[®] Technology, the dressings do not need to contain large amounts of silver to be able to produce sufficient concentrations of silver ions 'on demand' for antimicrobial action^{3,4}.

What is the evidence?

Laboratory studies of AQUACEL[®] Ag dressing have demonstrated:

- **broad spectrum antimicrobial activity³**
- **sustained antimicrobial activity (up to 14 days)^{3, 13}**

Additional clinical studies of AQUACEL[®] Ag dressings have demonstrated:

- **high absorption and fluid retention⁹**
- **reduced pain during wear and at dressing removal¹⁹⁻²¹**
- **easy application and removal²¹**.

Clinical evaluation of AQUACEL[®] Ag dressings has been undertaken in a wide range of wound types, including chronic leg ulcers²², diabetic foot ulcers²³, partial-thickness burns^{21,24,25}, surgical wounds²⁶ and wound cavities²⁷.

Why is ionic silver important?

High silver content or the total amount of silver made available by a dressing does not relate directly to greater antimicrobial activity⁸. This is because silver exists in several chemical forms. Silver metal (Ag) can only become effective as an antimicrobial agent when it transforms into silver ions (Ag⁺).

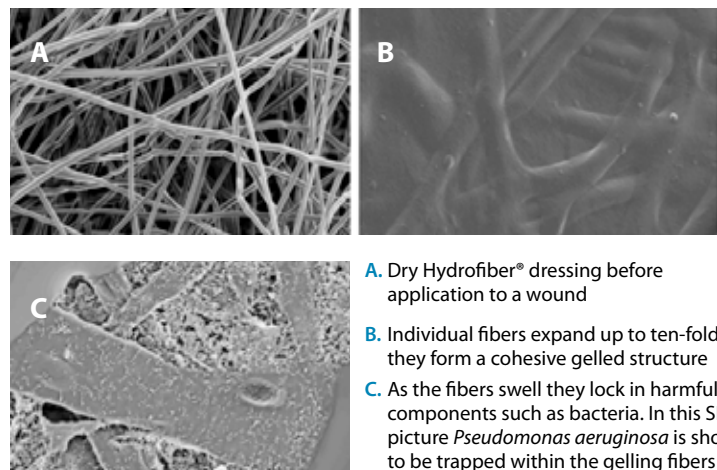
Silver ions damage bacterial cell walls and interfere with DNA synthesis. Silver ions also denature proteins and enzymes, and inhibit protein synthesis, killing the bacterium¹⁶. This multi-targeted mechanism of action means that ionic silver has a far lower propensity to induce bacterial resistance than classic antibiotics¹⁷.

AQUACEL[®] Ag dressings contain silver only in the ionic form (Ag⁺). The dressings act as a reservoir of silver ions by continually supplying a concentration that has effective antimicrobial action^{3,4}, while avoiding higher concentrations that may cause transient skin staining as seen during *in vitro* testing¹⁸.

AQUACEL[®] Ag dressings make ionic silver available in a controlled manner in

response to exudate levels, ie 'on demand'³. The amount of ionic silver available is limited by the maximum amount of silver ions that can get into solution, ie if exudate levels increase or ionic silver is consumed by antimicrobial action, the concentration of silver ions in the exudate drops and the dressing will release more to re-establish the maximum solution concentration³.

Figure 1 Scanning electron micrographs (SEM) of Hydrofiber[®] dressing (Courtesy of ConvaTec)



- A. Dry Hydrofiber[®] dressing before application to a wound
- B. Individual fibers expand up to ten-fold¹⁵ as they form a cohesive gelled structure
- C. As the fibers swell they lock in harmful components such as bacteria. In this SEM picture *Pseudomonas aeruginosa* is shown to be trapped within the gelling fibers

Figure 2 Micro-contouring (Courtesy of ConvaTec)



AQUACEL® Ag Dressing covered by DuoDERM® Extra Thin dressing applied to a simulated wound surface

Gelling commences as the AQUACEL® Ag Dressing absorbs exudate

AQUACEL® Ag Dressing forms an intimate contact with the simulated wound surface, limiting spaces where bacteria can thrive

(See Table 1 on page 5 for a summary of the evidence for AQUACEL® Ag dressings.)

In a study of lower limb arthroplasty wounds, AQUACEL® SURGICAL cover dressing was found to be associated with a lower blister rate, fewer surgical site infections and a lower incidence of delayed discharge²⁸. In addition to the clinical benefits of aiding healing, reducing pain and preventing wound trauma in a wide range of wound types, clinical studies have found that the AQUACEL® dressings have a longer wear time and, therefore fewer dressing changes are required compared to other dressings tested in these studies^{21,22,24-28}. This has numerous benefits, including a reduction in overall costs (eg staff time, materials costs) as well as a reduction in patient inconvenience.

When are the dressings appropriate?

AQUACEL® Ag Dressing may be used for the management of:

- **infected wounds or those at risk of infection**
- **partial thickness (second-degree) burns**
- **diabetic foot ulcers, leg ulcers and pressure ulcers**
- **surgical wounds**
- **traumatic wounds**
- **wounds that are prone to bleeding**
- **oncology wounds**
- **donor and recipient graft sites¹⁴.**

(NB: If the wound is clinically infected, the patient may require systemic antibiotics in conjunction with AQUACEL® Ag Dressing.)

AQUACEL® Ag Ribbon Dressing with Strengthening Fiber may be used for the management of:

- **tunnelling wounds**
- **diabetic foot ulcers**
- **sinus wounds**
- **fistulas**
- **abscesses (after incision and drainage)**

- **pilonidal cysts (after incision and drainage)**
- **other chronic or acute wounds²⁹.**

AQUACEL® Ag SURGICAL cover dressing may be used:

- **for wounds healing by primary intention (eg traumatic and elective postoperative wounds/incisions)**
- **to provide an effective barrier to bacterial penetration to help reduce infection³⁰.**

Contraindications

AQUACEL® Ag Dressing, AQUACEL® Ag Ribbon Dressing with Strengthening Fiber and AQUACEL® Ag SURGICAL cover dressing should not be used on individuals who are sensitive to or who have had an allergic reaction to silver or sodium carboxymethylcellulose^{14,30,31}.

Guide to application

AQUACEL® Ag Dressing and AQUACEL® Ag Ribbon Dressing with Strengthening Fiber

Please refer to the package inserts for complete directions for use^{14,31}.

Prepare the wound bed

Before any application of AQUACEL® Ag Dressing or AQUACEL® Ag Ribbon Dressing with Strengthening Fiber the wound bed should be prepared according to local policy. This will usually involve removal of necrotic or sloughy tissue. The wound should be cleansed and the skin around the wound thoroughly dried.

For wounds that are not deep

The AQUACEL® Ag Dressing chosen should be of sufficient size to overlap by 1cm (approximately 0.5 inches) onto the intact skin surrounding the wound. The dressing will shrink as it absorbs wound fluid and gels. The vertical absorption of exudate means that periwound maceration is less likely and that there may be no need to use methods to protect the wound edge. When there is any depth to

PRODUCTS FOR PRACTICE

the wound the dressing should be layered to fill the wound and avoid the creation of dead space.

If the wound bed is relatively dry, it is recommended that AQUACEL® Ag Dressing is placed in the wound and then moistened with sterile saline over the wound area only. The vertical absorption of the dressing will help to maintain the moist area over the wound only and reduce the risk of periwound maceration.

For partial thickness burns, AQUACEL® Ag Dressing should overlap 5cm (approximately 2 inches) onto the skin surrounding the burn. The dressing should be covered with sterile gauze and secured with medical tape or a retention bandage. In this situation, adherence of AQUACEL® Ag Dressing to the wound bed is a desired characteristic that helps to reduce the frequency of dressing changes^{21,24}. Lack of adherence within one to two days of dressing application

may indicate secondary deepening of the burn, or development of a complication such as infection, and indicate reassessment of the wound²¹.

For deep wounds

Select the appropriate width of AQUACEL® Ag Ribbon Dressing with Strengthening Fiber. When using AQUACEL® Ag Ribbon Dressing with Strengthening Fiber in deep wounds, at least 2.5 cm (approximately 1 inch) should be left outside the wound to aid retrieval of the dressings. Deep wounds should be filled with the dressing by no more than 80% (almost to the top), as the dressing will swell as it absorbs the fluid.

Apply a cover dressing

The dressing should be covered with a secondary dressing that keeps the wound moist. The choice of secondary dressing will depend on the level of exudation (eg for a lightly exuding wound DuoDERM® Dressing (ConvaTec)

or for a lightly to moderately exuding wound Versiva® XC® Gelling Foam Dressing (ConvaTec) may be appropriate). See individual package inserts for instructions regarding cover dressing usage and removal. If covering with gauze, the dressings should be changed when wound fluid strikes through the outer layer.

Removal

While the dressing may have to be changed every two to three days initially, it can be left on the wound for up to seven days when the wound is almost closed. The dressing should be changed when it is saturated with wound fluid or if the cover dressing's edges are bunching, rolling or leaking. The dressing should be removed when medically indicated (eg when wound fluid comes out of the dressing, there is too much bleeding, or there is increased pain). If residual dressing is left in the wound, irrigate with a

AQUACEL® Ag case study

This case study features a female patient with recurrent venous leg ulcers

This female patient, aged 77 years, has chronic venous insufficiency following a deep venous thrombosis years previously. Since 1990, she has had recurrent venous leg ulcers on the lower parts of both legs. The current ulcers, two on the left leg and one on the right, started in 2007.

The patient has severe arthritis of the left knee that limits her ability to walk less than 200 metres per day. She is on the waiting list for a knee replacement, but this cannot take place until the venous leg ulcers have healed. As a result, she was referred to the wound clinic in early 2010.

At the initial visit, the patient said that the wounds had increased in area, but was unclear by how much and over what period. She mentioned that she was currently experiencing more wound-related pain than usual. The ulcers were being treated with a paraffin-impregnated cotton viscose primary dressing and an absorbent cellulose fluff secondary dressing beneath Class I compression stockings.

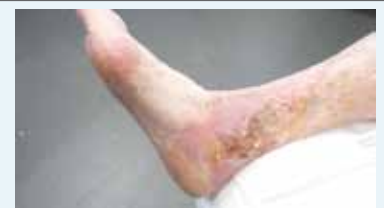The wound beds were green/yellow and producing considerable watery exudate. These signs, along with the increase in pain and wound area, indicated infection.

AQUACEL® Ag Dressing was chosen because of its antiseptic properties, high absorption and ease of use. At each dressing change, the ulcers underwent sharp debridement and cleansing with tap water-soaked gauze. The AQUACEL® Ag Dressing was covered with an absorbent cellulose fluff dressing that was held in place by an elasticated tubular bandage. The patient's stockings did not provide sufficient compression, and so ambulatory compression bandaging with short-stretch bandages was commenced.

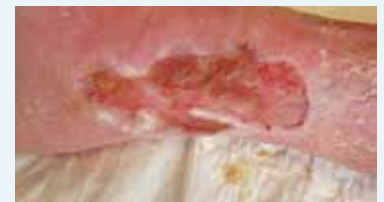The wound on the right lower leg is used here as an example (see pictures). On presentation, the wound area was 64cm². After five months of treatment, the condition of the wound bed had improved, there was visible granulation tissue and the area of the wound was 50cm². By the end of December 2010, the wound area had reduced to 6.5 cm². At the end of January 2011, the level of exudate production was so low that AQUACEL® Ag Dressing was discontinued.

Treatment was continued with an enzyme alginate. By the beginning of February 2011, the wound area had reduced further to 1.5 cm². The other two ulcers had healed and, because the oedema of the legs has resolved, the patient is now wearing therapeutic elastic stockings.

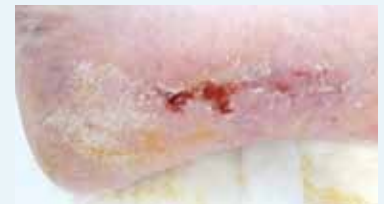In this case, AQUACEL® Ag Dressing antimicrobial and moisture retentive properties helped to promote healing in the patient's long-standing venous leg ulcers that were exhibiting signs of infection.



The wound on 25 January, 2010 (64cm²)



The wound on 30 June, 2010 (50cm²)



The wound on 2 February, 2011 (1.5cm²)

Table 1 Summary of clinical evidence for the AQUACEL® Ag

Reference	Title	Design	Criteria	Findings
Vanscheidt W, Lazareth I, Routkovsky-Norval C. <i>WOUNDS</i> 2003; 15(11): 371–78 ²²	Safety evaluation of a new ionic silver dressing in the management of chronic ulcer	Open label, multicentre, non-comparative study	Chronic leg ulcers (n=15)	<ul style="list-style-type: none"> 39% patients were assessed as having marked improvement and 56% mild improvement mean reduction in ulcer area was 23.9%; and 32.5% in ulcers that were infected at baseline
Jude EB, Apelqvist J, Spraul M, et al. <i>Diabet Med</i> 2007; 24: 280–88 ²³	Prospective randomized controlled study of Hydrofiber® dressing containing ionic silver or calcium alginate dressings in non-ischaemic diabetic foot ulcers	Phase III, open label, randomised, multicentre comparative	Non-ischaemic diabetic foot ulcers (n=134)	<ul style="list-style-type: none"> Mean healing time was 53 days for AQUACEL® Ag Dressing and 58 days for calcium alginate Ulcers managed with AQUACEL® Ag Dressing reduced depth nearly twice as much
Caruso DM, Foster KN, Blome-Eberwein SA, et al. <i>J Burn Care Res</i> 2006; 27(3): 298–309 ²¹	Randomized clinical study of Hydrofiber® dressing with silver or silver sulfadiazine in the management of partial-thickness burns	Randomised, controlled	Partial thickness burns (n=84)	<p>AQUACEL® Ag Dressing was associated with:</p> <ul style="list-style-type: none"> less pain and anxiety at dressing change over 50% fewer dressing changes fewer procedural medications
Paddock HN, Fabia R, Giles S, et al. <i>J Pediatr Surg</i> 2007; 42(1): 211–13 ²⁵	A silver-impregnated antimicrobial dressing reduces hospital costs for paediatric burns patients	Retrospective review of cost-effectiveness	Paediatric burns (n=77)	<ul style="list-style-type: none"> Total charges and direct costs were significantly lower for AQUACEL® Ag Dressing AQUACEL® Ag Dressing patients had shorter hospital stay
Jurczak F, Dugré T, Johnstone A, et al. <i>Int Wound J</i> 2007; 4(1): 66–76 ²⁶	Randomised clinical trial of Hydrofiber® dressing with silver versus povidone-iodine gauze in the management of open surgical and traumatic wounds	Prospective, randomised, open label, controlled Phase III	Open surgical and traumatic wounds (n=67)	<p>At final evaluation, AQUACEL® Ag Dressing was significantly better than povidone-iodine gauze for:</p> <ul style="list-style-type: none"> overall ability to manage pain wound trauma on dressing removal
Clarke JV, Deakin AH, Dillon JM, et al. <i>J Wound Care</i> 2009; 18(1): 5–11 ²⁸	A prospective clinical audit of a new dressing design for lower limb arthroplasty wounds	Clinical audit	Lower limb arthroplasty wounds (n=223)	<p>Wounds managed with the new dressing had:</p> <ul style="list-style-type: none"> lower blister rate fewer surgical site infections

wound cleanser. If the dressing dries and is hard to remove, it should be moistened according to local policy (eg with sterile saline or sterile water) and allowed to soak until it lifts easily.

AQUACEL® Ag SURGICAL cover dressing

Please refer to the package insert for complete directions for use³⁰.

Before application

The area around the wound should be cleansed according to local policy and dried thoroughly.

Application

The dressing size chosen should ensure direct contact between the Hydrofiber® Technology pad and all of the incision. Contact between the incision and

the hydrocolloid adhesive should be avoided. The AQUACEL® Ag SURGICAL cover dressing does not require a secondary dressing.

The dressing is flexible and extensible to aid comfort and ease of movement. Once applied, the dressing can be moulded into place. When applying the dressing to knees, it is recommended that the knee is bent at a 30 degree angle during application.

Removal

The dressing should be removed when clinically indicated, eg if there is excessive bleeding, leakage, suspicion of infection, or seven days after application. The dressing should be removed by pressing down on the skin with one hand and carefully lifting the edge with the

other hand. The adhesive seal can be broken by stretching the dressing.

Economics

Wound care remains a large cost burden for healthcare systems^{32,33} and wounds have a significant negative impact on patients^{34,35}. A review of several wound care audits has highlighted lack of appropriate diagnosis and wound management as a key driver of delayed healing³². Initiatives focused on improving the diagnosis and treatments of wounds are likely to significantly reduce costs³⁴.

AQUACEL® Ag Dressing reduced average healing time compared to a calcium alginate dressing in a study of patients with diabetic foot ulcers²³.

Healthcare practitioners are advised to consult the Package Insert for AQUACEL® Ag Dressing, AQUACEL® Ag Ribbon Dressing with Strengthening Fiber and AQUACEL® Ag SURGICAL cover dressing before applying any of these products to a wound. Supported by an educational grant from ConvaTec. The views expressed in this 'Made Easy' section do not necessarily reflect those of ConvaTec.

In a randomised comparison of AQUACEL® Ag Dressing with silver sulfadiazine in the management of patients with partial thickness burns, AQUACEL® Ag Dressing was associated with less pain and anxiety at dressing change, fewer dressing changes, less nursing time and fewer procedural medications²¹.

In addition, a study comparing length of hospital stay in paediatric burns patients treated with AQUACEL® Ag Dressing or silver sulfadiazine found that wounds managed with AQUACEL® Ag had significantly lower total and direct hospital costs per patient²⁵.

References

- Jones S, Bowler PG, Walker M. Antimicrobial activity of silver-containing dressings is influenced by dressing conformability with a wound surface. *Wounds* 2005; 17(9): 263–70.
- Bowler PG. Progression toward healing: Wound infection and the role of an advanced silver-containing Hydrofiber® dressing. *Ostomy Wound Manage* 2003; 49(8) (suppl): 2–5.
- Jones SA, Bowler PG, Walker M, Parsons D. Controlling wound bioburden with a novel silver-containing Hydrofiber® dressing. *Wound Repair Regen* 2004; 12(3): 288–94.
- O'Neill MAA, Vine GJ, Beezer AE, et al. Antimicrobial properties of silver-containing wound dressings: a microcalorimetric study. *Int J Pharmaceutics* 2003; 263: 61–68.
- Waring MJ, Parsons D. Physico-chemical characterisation of carboxymethylated spun cellulose fiber. *Biomaterials* 2001; 22: 903–12.
- Walker M, Hobot JA, Newman GR, Bowler PG. Scanning electron microscopic examination of bacterial immobilisation in a carboxymethyl cellulose (AQUACEL®) and alginate dressings. *Biomaterials* 2003; 24(5): 883–90.
- Hoekstra MJ, Hermans MH, Richeters CD, Dutrieux RP. A histological comparison of acute inflammatory responses with a hydrofiber or tulle gauze dressing. *J Wound Care* 2002; 11(3): 113–17.
- Parsons D, Bowler PG, Myles V, Jones S. Silver antimicrobial dressings in wound management: a comparison of antibacterial, physical, and chemical characteristics. *WOUNDS* 2005; 17(8): 222–32.
- Coutts P, Sibbald RG. The effect of a silver-containing Hydrofiber dressing on superficial wound bed and bacterial balance of chronic wounds. *Int Wound J* 2005; 2(4): 348–56.
- Robinson BJ. The use of a hydrofiber dressing in wound management. *J Wound Care* 2000; 9(1): 32–34.
- Walker M, Bowler PG, Cochrane CA. In vitro studies to show sequestration of matrix metalloproteinases by silver-containing wound care products. *Ostomy Wound Manage* 2007; 53(9): 18–25.
- Bishop SM, Walker M, Rogers AA, Chen WY. Importance of moisture balance at the wound-dressing interface. *J Wound Care* 2003; 12(4): 125–28.
- Bowler PG, Jones SA, Walker M, Parsons D. Microbicidal properties of a silver-containing Hydrofiber® dressing against a variety of burn wound pathogens. *J Burn Care Rehabil* 2004; 25: 192–96.
- AQUACEL® Ag Dressing. Instructions for use. ConvaTec Limited, 2010.
- Newman GR, Walker M, Hobot JA, Bowler PG. Visualisation of bacterial sequestration and bactericidal activity within hydrating Hydrofiber® wound dressings. *Biomaterials* 2006; 27(7): 1129–39.
- Lansdown AB. Silver I: its antibacterial properties and mechanism of action. *J Wound Care* 2002; 11(4): 125–30.
- Percival SL, Bowler PG, Russell AD. Bacterial resistance to silver in wound care. *J Hosp Inf* 2005; 60: 1–7.
- Walker M, Cochrane CA, Bowler PG, et al. Silver deposition and tissue staining associated with wound dressings containing silver. *Ostomy Wound Manage* 2006; 52(1): 42–50.
- Armstrong SH. Use of a fibrous dressing in exuding leg ulcers. *J Wound Care* 1997; 6(7): 322–24.
- Kogan L, Moldavsky M, Szvalb S, Govrin-Yehudain J. Comparative study of Aquacel® and Silver® treatment in burns. *Ann Burns Fire Disasters*. 2004; 17(4): 201–207.
- Caruso DM, Foster KN, Blome-Eberwein SA, et al. Randomized clinical study of Hydrofiber dressing with silver or silver sulfadiazine in the management of partial-thickness burns. *J Burn Care Res* 2006; 27(3): 298–309.
- Vanscheidt W, Lazareth I, Routkovsky-Norval. Safety evaluation of a new ionic silver dressing in the management of chronic ulcers. *Wounds* 2003; 15(11): 371–78.
- Jude EB, Apelqvist J, Spraul M, Martini J. Prospective randomized controlled study of Hydrofiber dressing containing ionic silver or calcium alginate dressings in non-ischaemic diabetic foot ulcers. *Diabet Med* 2007; 24(3): 280–88.
- Caruso DM, Foster KN, Hermans MH, Rick C. Aquacel Ag in the management of partial-thickness burns: results of a clinical trial. *J Burn Care Rehabil* 2004; 25(1): 89–97.
- Paddock HN, Fabia R, Giles S, et al. A silver-impregnated antimicrobial dressing reduces hospital costs for pediatric burn patients. *J Pediatr Surg* 2007; 42(1): 211–13.
- Jurczak F, Durgé T, Johnstone A, et al. Randomised clinical trial of Hydrofiber dressing with silver versus povidone-iodine gauze in the management of open surgical and traumatic wounds. *Int Wound J* 2007; 4(1): 66–76.
- Cartledge-Gann L. Consider the whole patient, not just the hole: healing a wound cavity by secondary intention. *Wound Pract Res* 2008; 16(4): 176–80.
- Clarke JV, Deakin AH, Dillon JM, et al. A prospective clinical audit of a new dressing design for lower limb arthroplasty wounds. *J Wound Care* 2009; 18(1): 5–11.
- AQUACEL® and AQUACEL® Ag Ribbon Dressing Instruction Sheet. ConvaTec Limited, 2010.
- AQUACEL® Ag SURGICAL cover dressing. Instructions for use. ConvaTec Limited, 2009.
- AQUACEL® Ag Ribbon Dressing. Instructions for use. ConvaTec Limited, 2010.
- Posnett J, Franks P. The costs of skin breakdown and ulceration in the UK. In: *Skin Breakdown – The silent epidemic*. The Smith & Nephew Foundation. 2007: 6–12.
- Drew P, Posnett J, Rusling L. The cost of wound care for a local population in England. *Int Wound J* 2007; 4(2): 149–55.
- Moffatt CJ, Franks PJ, Hollinworth H. Understanding wound pain and trauma: an international perspective. In: *European Wound Management Association (EWMA). Position Document. Pain at Wound Dressing Changes*. London: MEP Ltd, 2002.
- Herber OR, Schnepf W, Rieger MA. A systematic review on the impact of leg ulceration on patients' quality of life. *Health Qual Life Outcomes* 2007; 5: 44–56.

Author details

Queen D¹, Walker M², Parsons D³, Rondas A⁴.

- Honorary Research Fellow, Department of Dermatology and Wound Healing, Cardiff University, Cardiff, UK.
- Senior Research Advisor, ConvaTec Global Development Centre, Deeside, UK.
- Associate Director, ConvaTec Global Development Centre, Deeside, UK.
- Physician for the Elderly, MSc in Wound Healing and Tissue Repair (Cardiff, Wales), and PhD student at the University of Maastricht (CAPHRI), working for The Zorggroep, Venlo, The Netherlands.

Summary

AQUACEL® Ag is available as a flat sheet for superficial wounds (AQUACEL® Ag Dressing), a ribbon for packing deep wounds (AQUACEL® Ag Ribbon Dressing with Strengthening Fiber) and a waterproof dressing for surgical incisions (AQUACEL® Ag SURGICAL cover dressing). AQUACEL® Ag dressings combine Hydrofiber® Technology with ionic silver to produce a dressing material that is highly absorbent, has favourable gelling characteristics and broad-spectrum antimicrobial activity, and can be used to prevent wound infection.

To cite this publication

Queen D, Walker M, Parsons D, Rondas A. AQUACEL® Ag Dressings Made Easy. *Wounds International* 2011; 2(1): Available from <http://www.woundsinternational.com>